

ACP MESSENGER

Spring 2016

From simple to complex
Digital treatment planning
Computer-aided design

ACP

AMERICAN COLLEGE OF
PROSTHODONTISTS

Your smile.
Our specialty.®

IVOCLAR VIVADENT REMOVABLE

More than dentures.



Kristi Lind, Denture patient and blogger

SR Phonares® II

Natural esthetics for sophisticated smiles

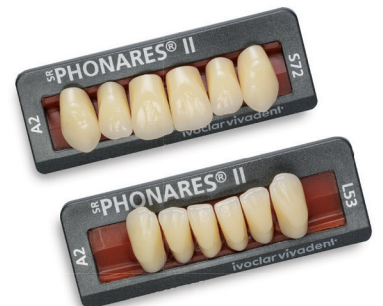Now, with Phonares II teeth, you can create more than a denture, you can create a smile! Phonares II premium denture teeth represents the latest innovation in material science, design and performance, providing the very best in esthetics, wear and natural smile design. Recommend Phonares II to your dentists because quality materials equals quality results.

Hear Kristi's story at iweardentures.com



ivoclarvivadent.com

For more information, call us at 1-800-533-6825 in the U.S., 1-800-263-8182 in Canada.
© 2016 Ivoclar Vivadent, Inc. Ivoclar Vivadent and Phonares are registered trademarks of Ivoclar Vivadent, Inc.



ivoclar
vivadent
passion vision innovation



We had our picnic spread out when all of a sudden the sky opened up. In a moment, we were soaked! I thought my daughter would be devastated, but she laughed and reminded me that April showers bring May flowers. That made me think about my prosthodontist – how the challenge of creating a treatment plan and the difficulty of changing my habits led to a healthy smile, which once seemed impossible. That’s the thing to remember: if you keep looking through the rain, you just might see beautiful things starting to bloom.

In Every Issue

- 6 From the Editor: A versatile specialty

- 8 Case Presentation: From simple to complex, the many facets of prosthodontics

- 12 At the Chair: Dental treatment for anterior teeth subjected to trauma

- 16 In the Office: The challenges of identifying an open digital workflow to restore dental implants

- 20 In the Lab: Computer assisted planning and manufacturing of implant surgical guides

- 30 Our Community

- 32 Classified Ads

Featured

- 23 From the ACP Leadership: Ready to lead

- 24 Leading the Industry: Harnessing the power of digital technology

- 26 Inside the ACPEF: Supporting innovative research

- 28 Annual Session Update

Editor-in-Chief

Mathew T. Kattadiyil, DDS, MDS, MS, FACP

Associate Editors

Susan E. Brackett, DDS, MS, FACP
Robert M. Taft, DDS, MS, BA, FACP

Editor Emeritus

Lyndon F. Cooper, DDS, PhD, FACP

ACP Board of Directors

Carl F. Driscoll, DMD, FACP, President
Susan E. Brackett, DDS, MS, FACP, President-Elect
Robert M. Taft, DDS, MS, BA, FACP, Vice President
Carol A. Lefebvre, DDS, MS, FACP, Secretary
Mark C. Hutten, DDS, MS, FACP, Treasurer
Frank J. Tuminelli, DMD, FACP, Immediate Past President
John D. Ball, DDS, FACP, Regional Membership Director – Central
Douglas G. Benting, DDS, MS, FACP, Director, Prosthodontic Forum
Lino P. Calvani, DDS, MSc, FACP, Regional Membership Director – International
Alan B. Carr, DMD, MS, FACP, Director, Education & Research
Nancy Deal Chandler, RHIA, CAE, CFRE, Executive Director
Lyndon F. Cooper, DDS, PhD, FACP, Chair, ACP Education Foundation
Betsy K. Davis, DMD, MS, Director, Maxillofacial Prosthetics
David A. Felton, DDS, MSD, FACP, Editor-in-Chief, *Journal of Prosthodontics*
David L. Guichet, DDS, FACP, Director, Continuing & Professional Education
Steven M. Morgano, DMD, FACP, Regional Membership Director – Northeast
Paul E. Scruggs, DDS, PA, Regional Membership Director – Eastern
Robert E. Stover, DDS, MS, FACP, Regional Membership Director – Pacific
Victoria A. Vickers, DDS, Director, Public Relations & Communications Division
Stephen A. Wagner, DDS, FACP, Director, Prosthodontic Practice & Patient Care Division
Alvin G. Wee, DDS, MS, MPH, PhD, Regional Membership Director – Rockies/Plains
William O. Wilson, Jr., DDS, MS, FACP, Regional Membership Director – Federal Services

ACP Central Office Staff

Nancy Deal Chandler, RHIA, CAE, CFRE, Executive Director
Mark Heiden, Associate Executive Director, Communications & Marketing
Melissa Kabadian, MA, CMP, Associate Executive Director, Education & Development
Carolyn Barth, Director, Public & Media Relations
Alethea Gerding, MA, Managing Editor, *Journal of Prosthodontics*
Jack Kanich, Finance and Administration Manager
Justin McDaniel, Membership Services Manager
Olivia Moukayed, Administrative & Education Coordinator
Adam Reshan, Director, Membership Services
Lauren Swanson, Communications & Marketing Manager
Nathalie Williams, Director, Sections & Governance

Managing Editor

Lauren Swanson

Advising Editor

Mark Heiden

Design

Publications Associates, Inc.

Display Advertising

Lisa Trinkle, M.J. Mrvica Associates, Inc.
Phone: (856) 768-9360
Email: ltrinkle@mrsvica.com

Classified Advertising

Visit Prosthodontics.org to download an insertion form. Email or fax the completed form to Lauren Swanson at lswanson@prosthodontics.org or (312) 573-1257. Classified ads are \$125 for the first 50 words and \$1 for each additional word for ACP members. The non-member rate is \$225 for the first 50 words and \$2 for each additional word. The minimum charge is \$125. Logos are an additional \$50, limited to one per ad and subject to approval. Payment by check, American Express, Visa, or Mastercard is required prior to placement.


The mission of the *ACP Messenger* is to inform readers about current prosthodontic trends, challenges, and successes. Statements of fact and opinion are the responsibility of the authors alone and do not imply an opinion on the part of the officers or the members of the ACP. The *ACP Messenger* annual subscription rate for members is \$45, which is included in membership dues. The U.S. subscription rate for Prosthodontic Forum Organization members is \$55 and \$65 for non-members. Canadian subscribers add \$5 each year; all other non-U.S. subscribers add \$10 each year.

The *ACP Messenger* (ISSN # 0736-346X) is published four times per year in the winter, spring, summer, and fall by the American College of Prosthodontists:

211 E. Chicago Ave., Suite 1000, Chicago, IL 60611
Phone: (312) 573-1260; Fax: (312) 573-1257
Email: acp@prosthodontics.org Website: Prosthodontics.org

© Copyright 2016 American College of Prosthodontists. All rights reserved. Materials may not be reproduced or translated without written permission. Contact the ACP for reprint permission.

Postmaster: Send address changes to the ACP Central Office at 211 East Chicago Avenue, Suite 1000, Chicago, IL 60611 or acp@prosthodontics.org.



Dr. John R. Agar is a past president of the ACP. He serves as Professor and Assistant Director, Graduate Prosthodontics at the University of Connecticut Health Center. He will serve as Program Chair of the 2016 Annual Session.

► Page 28



Dr. Carl F. Driscoll is President of the ACP and serves as Program Director for the Department of Graduate Prosthodontics at the University of Maryland.

► Page 23



Dr. Mathew Kattadiyil is Professor and Director of the Advanced Specialty Education Program in Prosthodontics at Loma Linda University School of Dentistry, and Editor-in-Chief of the *ACP Messenger*.

► Page 6




Dr. Lisa S. Strauch maintains a full time private practice in Lake Oswego, OR. She serves as the President of the ACP Oregon Section.

► Page 12




Dr. Peter R. Barndt is the Digital Dentistry Specialty Leader for the Navy Dental Corps and serves as a member of the Digital Dentistry Task Force for the ACP.

► Page 16



HMI Arnel Galapir, Master CDT, TE, CDA is a dental laboratory technician with training in maxillofacial prosthetics, and is the Leading Petty Officer of the Maxillofacial Prosthetics Laboratory at the Naval Postgraduate Dental School in Bethesda, MD.


► Page 20



Dr. Caroline T. Nguyen is the Vice President of the Association of Prosthodontists of Canada and chair of the ACP Poster Session. She serves as the Provincial Practice Leader in Prosthodontics at the BC Cancer Agency and Assistant Professor at the University of British Columbia.

► Page 8

QUINTESSENCE PRESENTS NEW TITLES IN PROSTHODONTICS




Edited by
John Beumer III | Robert F. Faulkner | Kumar C. Shah | Peter K. Moy

Fundamentals of Implant Dentistry, Volume 1: *Prosthodontic Principles*

The authors of this definitive textbook cover the full range of restorative treatment options for edentulous and partially edentulous situations, from relatively simple problems that

can be handled by a solo practitioner to those with substantial prosthodontic complexities, periodontal compromise of existing dentition, and significant bone and soft tissue defects. This groundbreaking work provides the kind of unrivaled insight that can ensure the highest degree of clinical success in prosthetic restoration, and it is destined to become the definitive textbook and desk reference for dental students and practitioners alike.

456 pp; 1,105 illus; ©2015;
ISBN 978-0-86715-585-3 (B5853); **US \$168**




J. Robert Kelly

Ceramics in Dentistry: *Principles and Practice*

This book unlocks the mystery behind successful use of dental ceramics and lays bare the science behind this high technology. The author shows how and why fracture occurs and explains why choosing the right material, design, and processing method are vital to the success of

any ceramic restoration and why certain ceramic systems are most suitable for certain clinical situations.

128 pp (softcover); 176 illus; ©2016;
ISBN 978-0-86715-653-9 (B6539); **US \$39**




Edited by
Sillas Duarte, Jr

Quintessence of Dental Technology 2016

A selection of the newest materials and best fabrication techniques for esthetic restorative results are elegantly presented in QDT 2016. Original articles on minimally invasive procedures, CAD/CAM, difficult cases, and the ever-challenging transition

zone take center stage this year. The State of the Art article features full-mouth esthetic rehabilitation of the severely worn and compromised dentition, and the Biomaterials Update focuses on self-etching ceramic primer.

224 pp; 933 illus; ©2016;
ISBN 978-0-86715-723-9 (J0627); **US \$132**



J. William Robbins | Jeffrey S. Rouse

Global Diagnosis: *A New Vision of Dental Diagnosis and Treatment Planning* (Book/CD-ROM set)

The emphasis in the Global Diagnosis system is to determine the etiology of the aberrant gingival positions prior to treatment. The power of the system is that the diagnosis leads to the treatment

plan. This book explains the Global Diagnosis system and shows how to diagnose and treat patients based on five CORE questions. Included is a CD with the CORE template, which allows readers to input diagnostic photographs and information to facilitate record keeping.

244 pp; 598 illus; ©2016;
ISBN 978-0-86715-523-5 (B5235); **US \$148**



TO ORDER

CALL: (800) 621-0387 (toll free within US & Canada) • (630) 736-3600 (elsewhere)
FAX: (630) 736-3633 **EMAIL:** service@quintbook.com **WEB:** www.quintpub.com

QUINTESSENCE PUBLISHING CO INC, 4350 Chandler Drive, Hanover Park, IL 60133

A versatile specialty

Mathew T. Kattadiyil,
DDS, MDS, MS, FACP
ACP Messenger Editor-in-Chief

The versatility of prosthodontics never ceases to amaze me. At the scientific meetings I have attended recently, I could sense an air of expectation of learning, seeing, and experiencing something new, from thousands of attendees.

This is dentistry, dental education, and of course prosthodontics at its finest, attracting incredibly talented clinicians, technicians, and experts in the industry. These individuals willingly share their knowledge, showcase new techniques, and inspire their colleagues to achieve more success in their patient care and treatment outcomes. These workshops and symposiums are geared towards providing updated information and procedures ranging from the simple to the complex.

One cannot help but leave these meetings feeling energized and eager to return to practice to try a ‘new technique’ or maybe a new device or a product. I see the same reaction amongst my graduate students who return from the scientific meetings and the Annual Session hosted by the ACP – excited and energized after learning a new concept, and eager to incorporate what they have learned into a patient treatment of their own.

These are exciting times and digital technology continues to capture our imagination, which is reflected in this edition of the *ACP Messenger*. In her case presentation, Dr. Caroline Nguyen describes how a complex dental problem was solved through a series of simple steps, while Dr. Lisa Strauch shows how an experience that appears complicated and

intimidating for a patient can be transformed into an opportunity for healing.

The technology involved in these treatments may appear complex at first look, but here, too, sharing our knowledge is the key. In his article, Dr. Peter Barndt provides a valuable reference for the digital workflow involved in a single implant restoration, and Master CDT Arnel Galapir delves further into how dental implants can be planned and restored with advanced software for the prosthodontist and dental technician.

Elsewhere in this issue, we hear from young researchers whose work was supported by the ACP Education Foundation, and Dr. John Agar previews the next ACP Annual Session in San Diego, which exemplifies prosthodontics at its finest. After all, we can only gain mastery of these new tools and techniques through our shared commitment to improving education, research, and practice.

We hope you enjoy reading about how prosthodontists perform complex treatments that bring about simple, beautiful outcomes: the happy and healthy smiles of our patients. ■



From simple to complex, the many facets of prosthodontics

Caroline T. Nguyen,
DMD, MS, FACP, FRCD(C)

As prosthodontists, we face challenging cases every day. Some are simpler than others. Deciding how best to address our patients' needs can seem difficult at first, but any complex treatment can be reduced to more simple components with careful planning.




Fig. 1: Pre-treatment photograph of the patient.

I would like to introduce you to Ben. His dental problems seemed overwhelming at first, but his treatment was simplified by approaching each step in a logical sequence. Ben was 62 years old when he came to the University of Maryland prosthodontic clinic for treatment. “My lower teeth are short and I have cracks in them,” he said. “Also, I bite my cheeks and it’s painful.”

At that time, he was seeing a dentist twice a year for check-ups and cleanings. He said that, in the past, he would have his teeth extracted whenever there was something wrong with them because “that’s what we used to do in those days.” His teeth were so worn that he would not smile (Figure 1). He also had a history of clenching and TMJ problems. His back teeth did not contact, causing him to slide his lower jaw forward to bite on his anterior teeth. Since he was missing most of his posterior teeth, Ben was biting and chewing with his front teeth. This resulted in attrition/wear on all his remaining anterior teeth (Figure 2).

The ‘provisional’ phase was the most delicate of all our treatment. It turned out Ben was very fond of Jaw Breakers candy, and he was biting on them throughout the day.

Following a complete exam, diagnosis, and initial caries control, I remember staring at the diagnostic casts for a few hours, wondering what I could do that would allow us to save Ben's remaining teeth while giving him proper chewing function. After a lot of thought and discussion with my faculty, a few treatment options were presented to Ben so he could make an informed decision. These options included complete dentures, a combination of crowns on his natural teeth and removable partial dentures, and a combination of crowns on his teeth and dental implants to replace his missing posterior teeth.

After reviewing the options, Ben laughed and said, "If I win the next lottery jackpot, maybe we can go for the implants, but for now, let's take the middle option and get crowns and plates."

Diagnostic wax patterns were made to determine the shape and size of the teeth, and prior to teeth preparations, an occlusal device was fabricated for his lower teeth to treat his TMJ problems. Ben was very comfortable with no signs of TMD after wearing the device full-time for 8 weeks and mentioned he felt his jaw muscles were a lot more relaxed. At this point, teeth preparations were performed, and provisional or temporary restorations were made based on the diagnostic wax patterns to ensure that Ben would like the appearance of his new taller teeth and could adapt to a proper occlusion ('bite') with anterior guidance.

This 'provisional' phase was the most delicate of all our treatment. It turned out Ben was very fond of Jaw Breakers candy, and he was biting on them throughout the day. Not only did that put him at an increased risk for caries, but his initial two weeks ended with a lot of fractured and loose crowns. After realizing his crowns would be more likely to fracture if he continued this

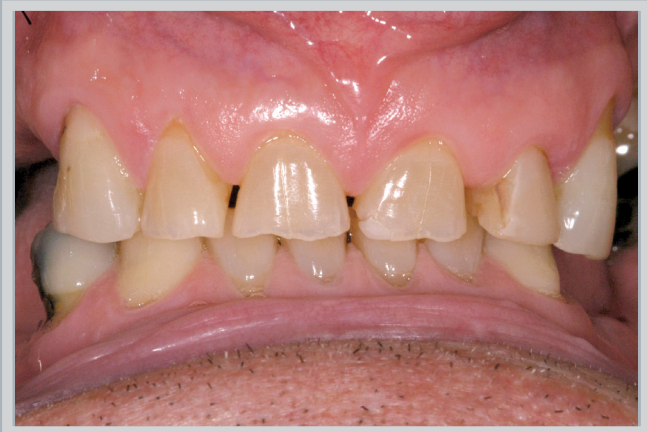

Fig. 2: Frontal view of the patient's teeth prior to treatment.

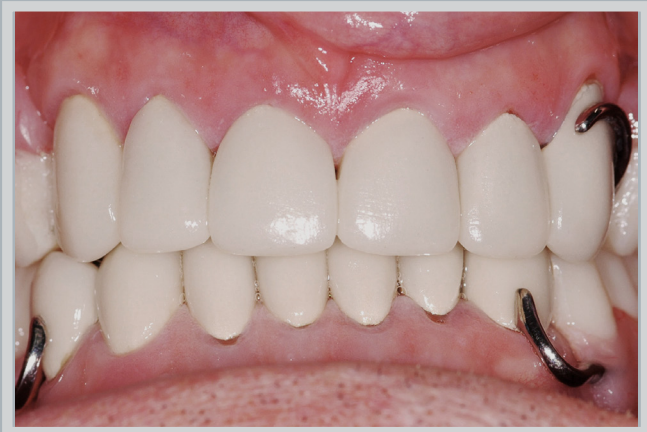

Fig. 3: Frontal view of the patient's teeth following treatment.

habit, Ben agreed to switch to sugar free hard candy – and to let the candy melt in his mouth instead of biting into it.

After a few weeks, Ben was able to adapt to this new "candy habit", and he indicated his pleasure with the shape/looks of the teeth. He also tolerated the changes

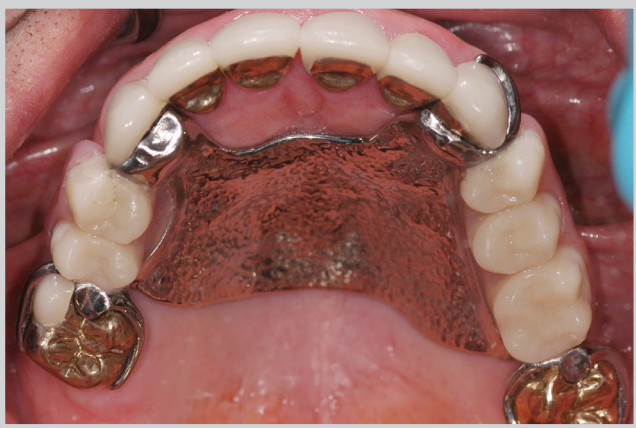

Fig. 4: A view of the upper teeth following treatment.

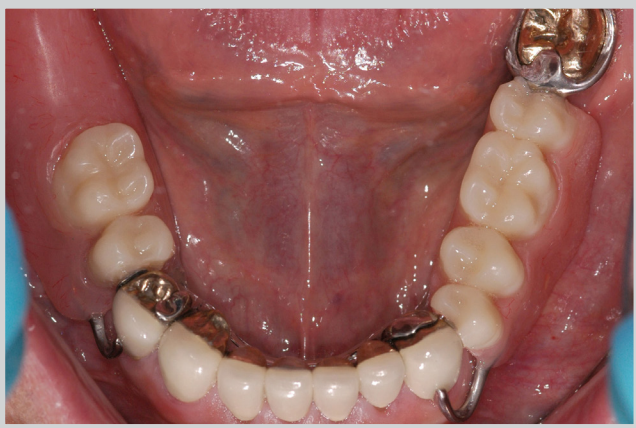

Fig. 5: A view of the lower teeth following treatment.

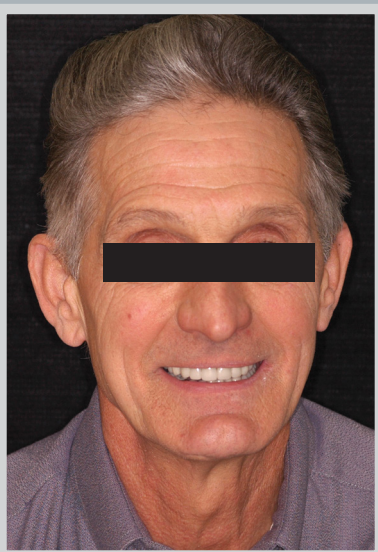


Fig. 6: A happy and satisfied patient following treatment.

in the height of his teeth and his ‘bite’, allowing us to proceed with the fabrication and cementation of the crowns. All final restorations were placed and meticulously checked for accuracy of fit, contour, esthetics, phonetics, and ‘bite’/occlusion was verified prior to cementation.

Impressions were made, and upper and lower removable partial dentures were fabricated and placed, paying special attention to maintaining the new occlusion (‘bite’) that was adjusted and refined in Ben’s mouth (Figures 3, 4, 5).

Ben was quite happy with the result and started smiling again with his teeth now clearly visible (Figure 6).

Considering Ben’s history of temporomandibular joint disorders (TMJ/TMD), worn teeth, and recurrent caries, we discussed ongoing maintenance of his teeth. We reinforced the need to maintain his new sugar free candy habit, and he was informed that his teeth could still be susceptible to caries even if they were crowned. Ben was also instructed to use high fluoride content prescription toothpaste. A new occlusal device was fabricated and he was told to wear it at night and when performing stressful activities to protect his teeth.

On the last day of active treatment, Ben laughed and said, “This is gonna be so weird not to have to visit anymore... I was seeing you more often than my daughter!”

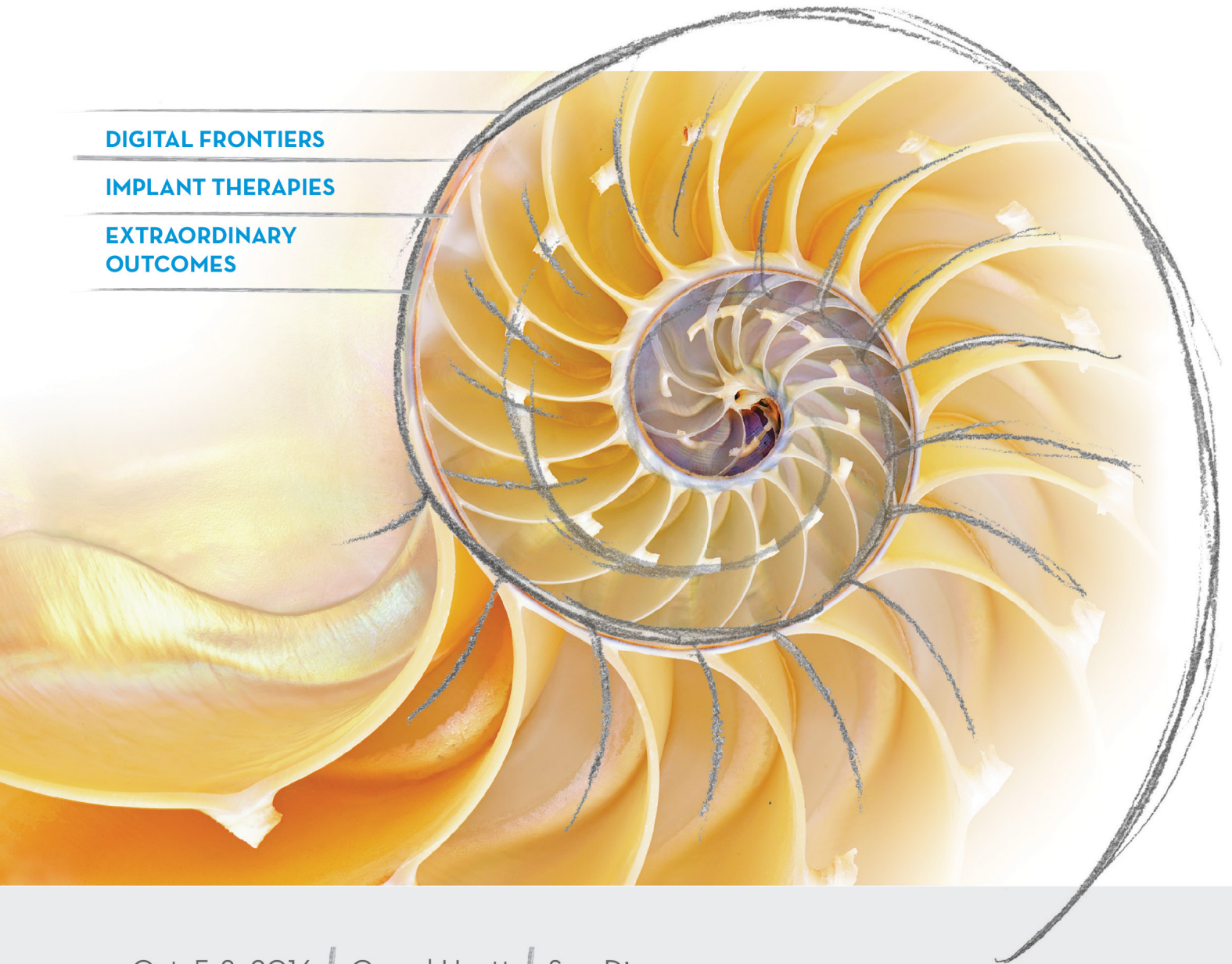
Ben continued to come for follow-up visits every six months, always with a bright, wide smile. He always had a very positive attitude and was extremely dedicated, motivated, and enthusiastic toward maintaining his newly achieved optimal oral health, ensuring the treatment outcome continues to be successful. ■

Prosthodontics: The Intersection of
ART & TECHNOLOGY

DIGITAL FRONTIERS

IMPLANT THERAPIES

EXTRAORDINARY
OUTCOMES



Oct. 5-8, 2016 | Grand Hyatt | San Diego
Registration opens in May | acp46.com

Dental treatment for anterior teeth subjected to trauma

Lisa S. Strauch,
DMD, MDS, FACP

Nothing is more disconcerting than seeing a patient who has had trauma to their anterior teeth for an initial consultation. Often the patient is young and accompanied by a worried parent. The patient may or may not have undergone orthodontics or have a fully erupted dentition.

Emotions and expectations are high. These patients have usually seen many providers including the pediatric dentist, general dentist, orthodontist, and endodontist. The patient and parent have heard many treatment options and are often confused regarding the treatment of choice and sequence.

At this point, we pause to reassure the patient and parent that they are in the right place. As prosthodontists, we are experts at explaining the complexities of anterior restorations. We understand the material choices, the prognosis and complications of teeth that have undergone trauma, and how implants are often the treatment of choice as the patient matures and completes growth. We reassure the worried party that we will make every effort to restore the patient's beautiful smile.

Now, let us reflect on the opposite end of the spectrum: an adult patient who presents with a broken front tooth. We quickly discover that this tooth had trauma when the patient was a child. After two root canals and a crown later, the tooth is now non-restorable. The patient is distressed and cannot comprehend why more dental treatment is required since he/she has been through so much. Expectations are high and treatment is required immediately to achieve a good prognosis.

Described herein are two sample scenarios that a prosthodontist would experience in practice. Treating patients with trauma to the anterior teeth requires a comprehensive understanding of restorative dentistry. We use our expertise and knowledge to explain the recommended treatment, other specialists that would need to be involved, and offer reassurance.



Working with the pediatric dentist and endodontist is sometimes essential and critical for creating a clear treatment path for the patient. For the patient, it creates expectations regarding treatment cost, time, and future treatment needs and the prosthodontist should take the lead role in addressing these concerns. Restorative prognosis can be established based on the extent of the trauma. The extent of trauma and age of the patient directs the prosthodontist towards either repairing the traumatic tooth with a full coverage restoration (crown/cap) or replacing the tooth with a dental implant supporting a crown/cap. Candid

conversations about the complications of the dental treatment mold the patient's expectations and create an understanding that teeth that have been damaged by trauma will require a lifetime of maintenance.

Spending the time to explain the complexities of dental treatment to the patient and parent is critical. Examples of common complications of traumatic teeth include darkening of tooth structure, a grey shadow seen through the gum tissue, gingival asymmetry (uneven edges of the gum tissue associated with the teeth), fracture of the tooth structure, vertical root fracture, extraction, and subsequent dental implant treatment.

Case 1: Incomplete Growth

In the first case discussed, the patient was referred by the pediatric dentist for a prosthodontic consultation. The 9-year-old patient presented with a broken right front tooth (#8) after hitting his tooth on his knee while jumping on a trampoline. The patient had already seen the endodontist for evaluation and treatment of the damaged nerve, which required a root canal.

The restorative treatment proposed and rendered was a foundation restoration on tooth #8 and a full coverage, layered ceramic crown. The left front tooth (#9) was reshaped at the incisal edge. The patient's mom was informed that he would most likely require orthodontic treatment in the future, but he could now be confident that his tooth had been restored and he could function normally.

His mom was very happy and relieved.

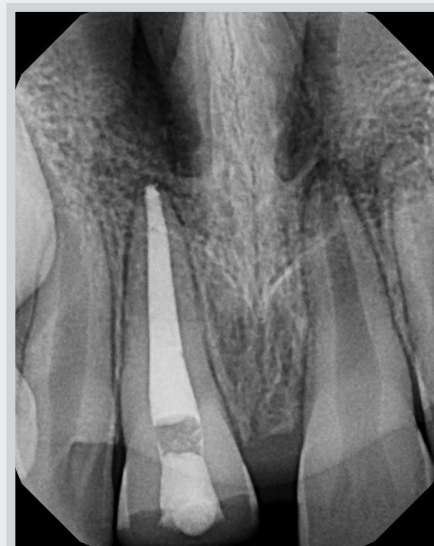

Fig. 2: Initial radiograph.

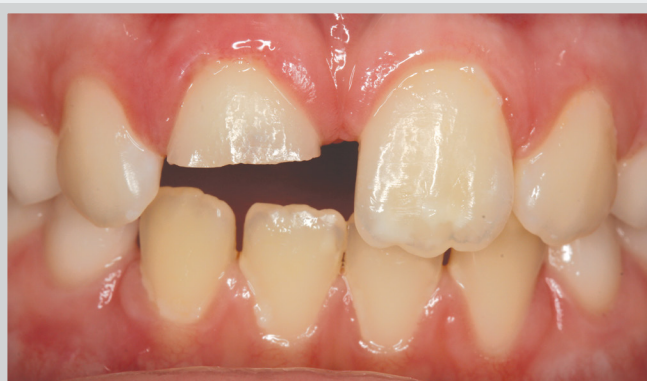

Fig. 1: Initial presentation: 9-year-old patient with a fractured tooth #8.

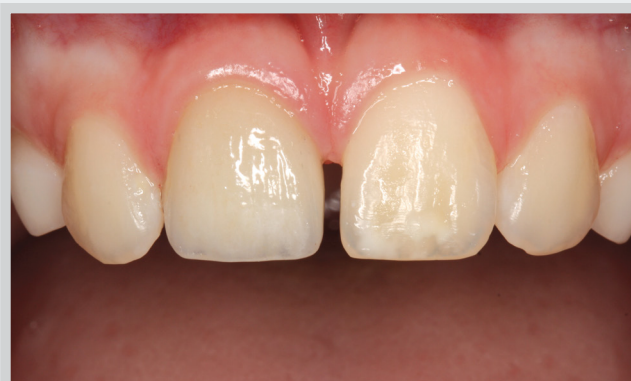

Fig. 3: Final restoration of #8 with a layered ceramic full coverage restoration and recontoured #9.

Case 2: Complete Growth

In the second case, the patient was an adult with a history of trauma to her front teeth. The general dentist referred the patient for a prosthodontic consultation after the patient's left front tooth (#9), which had already been restored with a crown (as a result of prior trauma), broke off at tissue level on Christmas day.

As emergency treatment, the #9 crown had been temporarily fixated using Ribbond and resin composite. Tooth #9 was deemed non-restorable and an implant restoration was planned for the #9 site.

The patient was also interested in replacing the crown on tooth #7 due to its poor shape and color. To achieve an optimum esthetic result, all four front teeth (#7, #8, #9, and #10) were treatment planned for complete coverage ceramic crowns. In-office tooth whitening was also initially performed to modify the shade of her teeth.

The surgical treatment plan was extraction, implant placement, and immediate placement of a temporary crown for #9. Gingival recontouring was also planned to idealize the appearance of the gum tissue and the final crowns. The surgical phase of treatment was executed as planned by the periodontist and then the patient was referred back to the prosthodontist for her restorations after complete healing. Layered all-ceramic lithium disilicate crowns were chosen for the full coverage crowns and a customized zirconia abutment was the material of choice for the implant abutment.

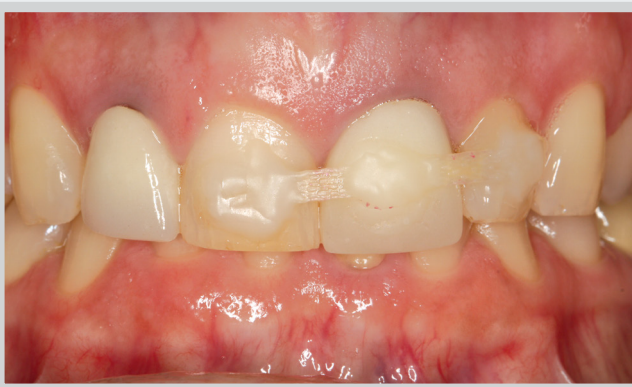

Fig. 4: Initial presentation: #9 fixated using Ribbond and resin composite.

The patient was pleased with a new and improved smile after many years of dissatisfaction with the appearance of her previous crowns. ■

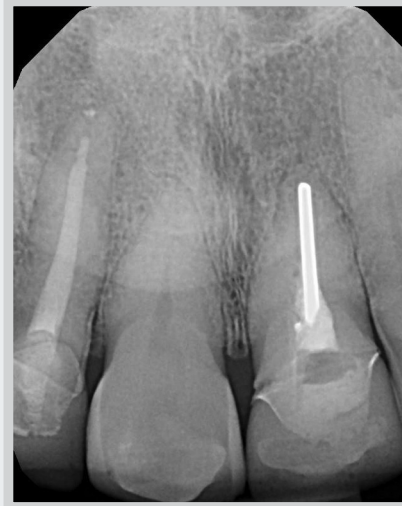

Fig. 5: Initial radiograph.

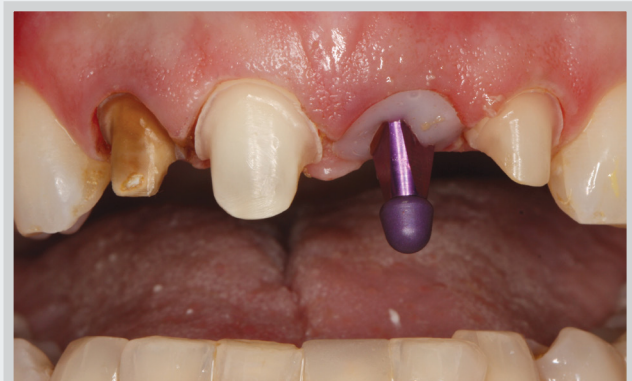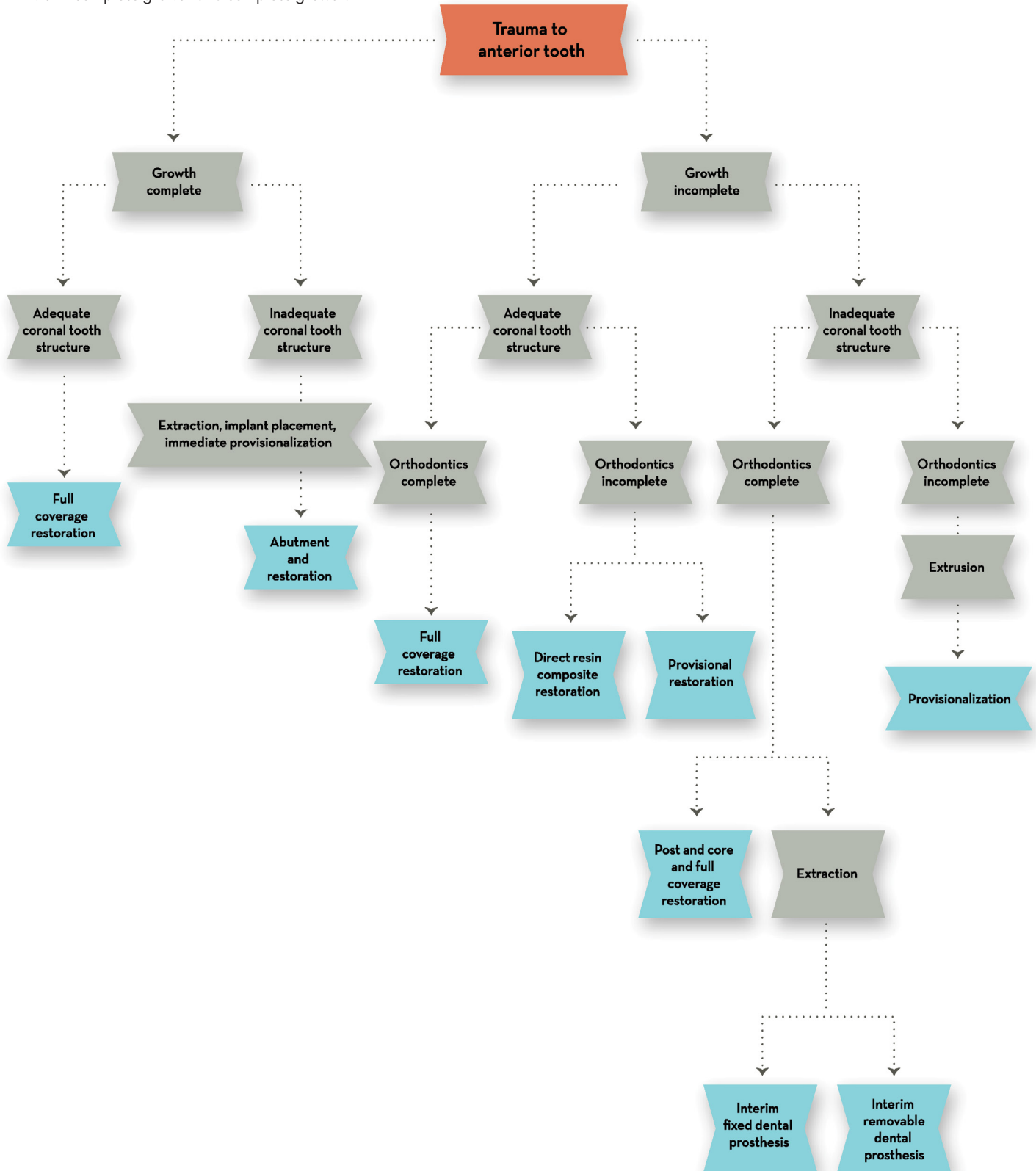


Fig. 6: Tooth preparations and customized closed tray impression post.

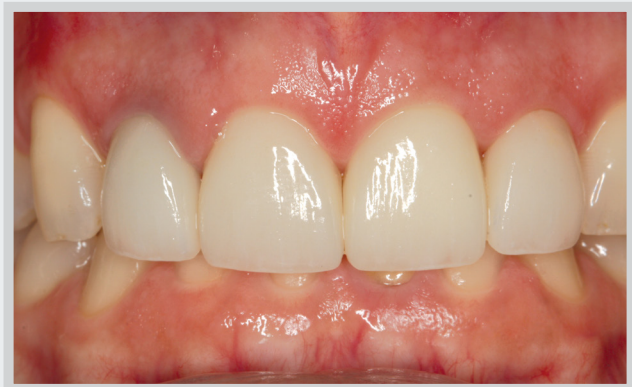

Fig. 7: Final restorations utilizing layered ceramic restorations and a zirconia abutment for #9.

Fig. 8: Flowchart comparing treatment options for patients with incomplete growth and complete growth.



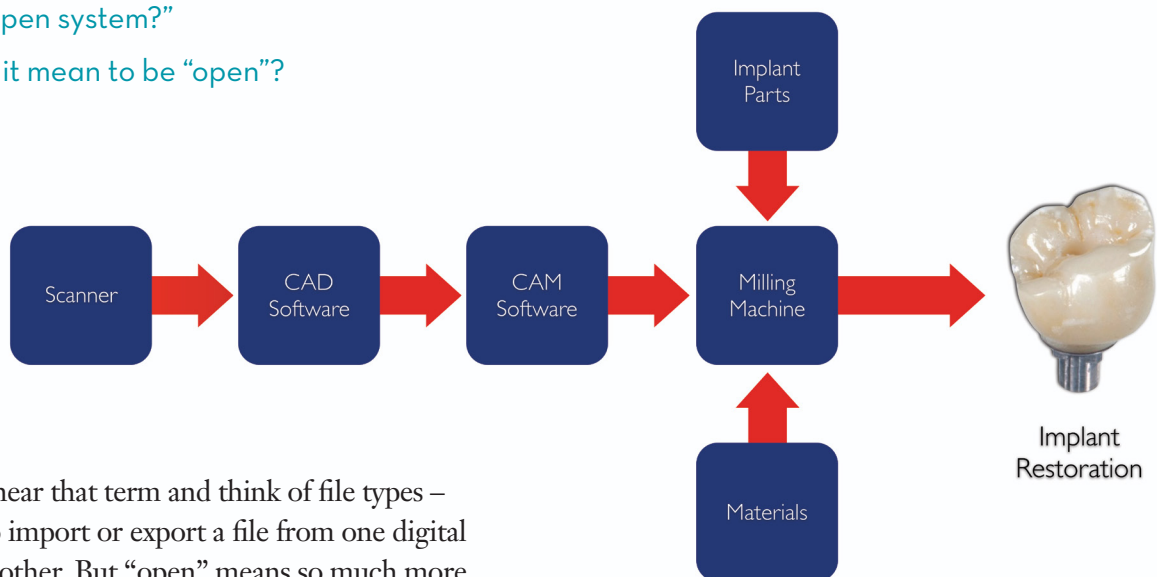
The challenges of identifying an open digital workflow to restore dental implants

Peter R. Barndt,
DDS, MDS

How many times have you heard the question

“Is this an open system?”

What does it mean to be “open”?



Many of us hear that term and think of file types – the ability to import or export a file from one digital system to another. But “open” means so much more than simply moving a file between two software applications. This article will focus on a completely digital workflow for a single implant restoration. Let’s start from a global view by considering all of the factors. When a provider decides to fabricate a single implant restoration from an intraoral scan, the elements in Figure 1 comprise the digital workflow.

Any of these factors, including design software, materials, implant components, and milling system could influence the restorative options of the prosthodontist. It is impractical to own multiple digital systems to meet all the unique requirements of the clinical practice. The key is obtaining a singular, yet flexible digital workflow that meets the full spectrum of prosthetic needs. In an open workflow, a provider can follow the same clinical protocol each time, with the same software, hardware, and components to reach a full complement of restoration types and materials.

Fig. 1: A completely digital workflow for single implant restorations.

To illustrate this point, I would like to focus on one small component of the digital workflow for a single implant restoration – the implant scan body. As an example, a 5mm implant is used. Figure 2 illustrates the traditional role an implant scan body plays in a digital workflow moving from the scan to design steps.

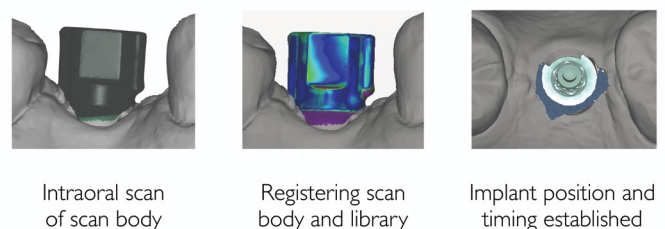


Fig. 2: Registering implant position with a scan body in a digital workflow.



Fig. 3: A sampling of scan body choices.

Figure 3 presents a small sampling of scan bodies available for use with this implant.

Although seemingly insignificant in the digital workflow, the choice of scan body can influence processes far beyond establishing implant position from an intraoral scan. Each scan body comes with an associated library for the CAD (Computer Aided Design) software that controls these critical features:

1. Position of the implant platform.
2. Rotational orientation of connection geometry.
3. Implant analog shape/design for use in a printed model.
4. The CAD restoration base output (3 possibilities):
 - ti-base interface
 - abutment preform position for milling
 - implant connection geometry

The registration and positioning features were illustrated in Figure 2. The ability to produce a printed model simply depends on the library containing an

implant analog shape and design. This can be used to design a model for printing, with a precise cavity to hold an implant analog. The last feature, the CAD restoration base output, is the most critical feature for an open workflow. This is the base of the designed restoration and controls manufacturing choices. Figure 4 demonstrates the restoration base outputs relative to an implant analog, with a black dashed line denoting the contour of an abutment.

Output of the implant connection with the CAD design allows the restoration to be milled from a disc of any material. This process requires the proper CAM (Computer Aided Manufacture) software and milling machine for accuracy, but provides the most design and material flexibility. The contour of the restoration can be controlled right to the edge of the implant platform. The ti-base restoration output creates an internal shape in the restoration suitable for luting of a ti-base. The small gap between the restoration and the analog is due to the bevel and small collar of the ti-base. Finally, preform base output allows an abutment to be milled from a titanium cylinder with a pre-machined collar and implant connection. Preform cylinders are currently only offered for purchase in titanium alloy.

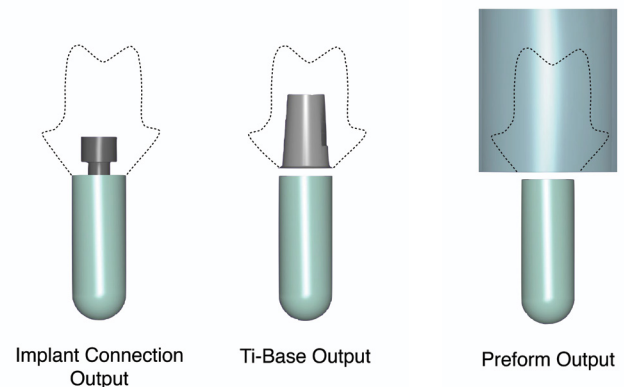


Fig. 4: The three types of CAD restoration base output.

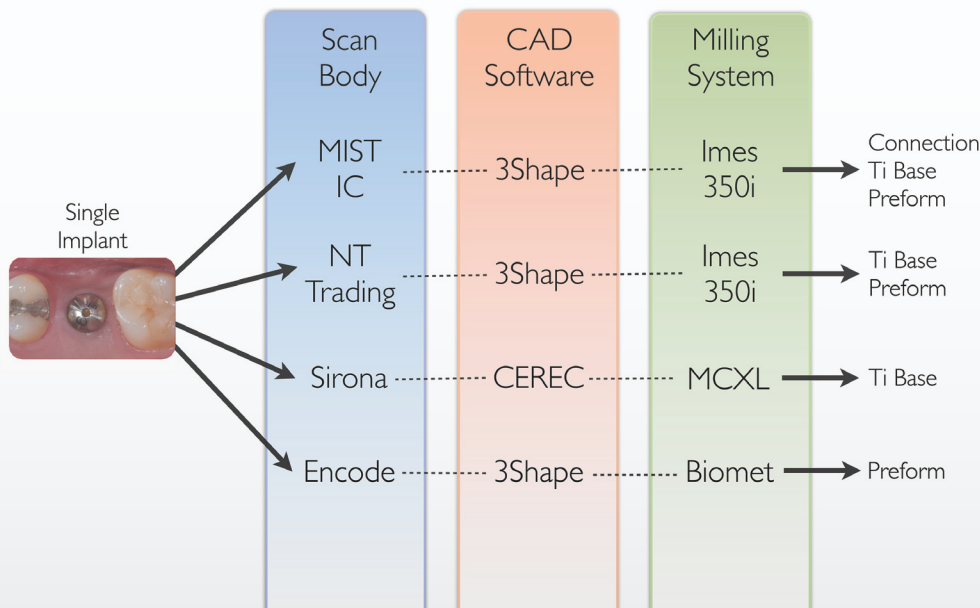


Fig. 5: Scan bodies and their respective CAD restoration base output.

The critical factor in this process is the vendor that supplies the scan body (and library) also controls the base output from the design software. This output may direct you to vendor-specific materials, implant components, or manufacturing. Not all restoration designs and materials are available from every scan body, and even fewer provide the restoration base output required for milling from a disc. Figure 5 demonstrates the CAD restoration base output of four scan body brands and an associated workflow.

The specific needs of the patient may not be identified until the CAD restoration contours are created. It is critical that laboratories have CAD/CAM flexibility that can accommodate unforeseen design needs and move forward with fabrication. Figure 6 presents a matrix of implant restoration types and materials and indicates which combinations are possible following each scan body and associated workflow.

Can you believe that the simple scan body can have such a profound impact on the restoration material or design? This is the subtlety of closed workflows in digital dentistry. As providers, we first need a global view of all the implant restorations that can be

generated from CAD/CAM. These possibilities go beyond what we are historically accustomed to. Only with this perspective can you make educated decisions about the restoration materials and design types useful to your clinical practice. Scan body selection follows all of this, using the following criteria to make the final selection:

1. What type of implant designs/materials do you want to utilize?
2. What scan bodies will your partner laboratory accept?
3. If you have a practice-lab, what do you want to manufacture in-house?
4. Is there a solution for printed implant models?

Answering these four questions will minimize future surprises. If you are using a closed workflow, you may have been unknowingly limiting your restorative options. In my estimation, vendors have recognized the need for options and are changing their business approaches. Open digital workflows are the key to your success with digital dentistry. ■

	One Piece Abutment	Hybrid Abutment	One Piece Screw Retained Crown	Hybrid Screw Retained Crown
Titanium	1 2 4	1 2	1	1 2
PMMA	1	1 2	1	1 2
e.max	N/A	3	N/A	3
CrCo	1	1 2	1	1 2
Zirconia	1	1 2 3	1	1 2 3

1 MIST IC

2 NT Trading

3 Sirona

4 Encode

Fig. 6: Scan body selection applied to an implant restoration design/material matrix.



Get Ready for the Second Edition! September 30 - October 1, 2016

“The Esthetic Zone Inside and Out” by Dr. Gerard Chiche at the TPC Sawgrass Clubhouse

TPC Sawgrass, 110 Championship Way, Ponte Vedra Beach, Florida 32082

BOOK NOW and SAVE!

13 CE Credits Total	Before 9/2	After 9/3
Dentist (2 days)	\$2200	\$2500
Dentist (Lecture only)	\$1400	\$1600
Dentist (Hands-on only)	\$950	\$1150
Student (2 days)	\$1100	\$1250
Student/Technician (Lecture only)	\$700	\$800

Contact ADES for group discount rate.

Guest Speaker: Markus B. Blatz, DMD, PhD
“CAD/CAM and Bonding Materials Update”



Visit www.academyofdes.org to read our testimonials and see our photo gallery from the first seminar in November 2015! Visit often as new seminar details will soon be announced.



info@academyofdes.org / 781-388-0016
Like AcademyofDES on Facebook



ADES, The Educational Division of Cusp Dental

Computer assisted planning and manufacturing of implant surgical guides

HMI Arnel Galapir,
Master CDT, TE, CDA

The routine fabrication of dental implant surgical guides has undergone significant changes over the past 10 years. Traditionally, we have fabricated implant surgical guides using poly(methyl methacrylate) (PMMA) and vacuum formed templates from dental wax patterns of the proposed restorations.

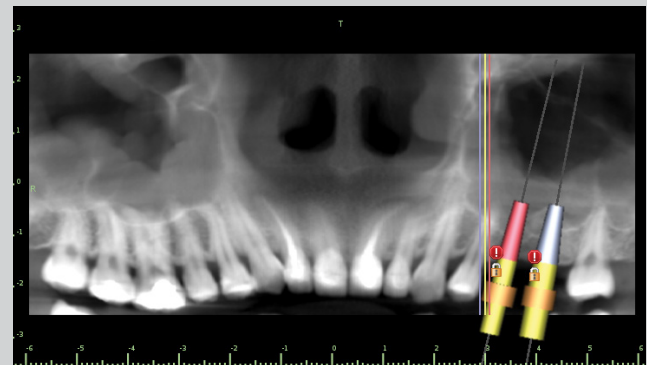
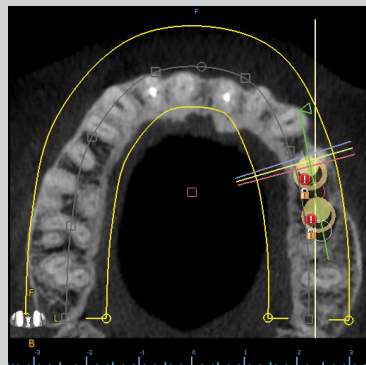
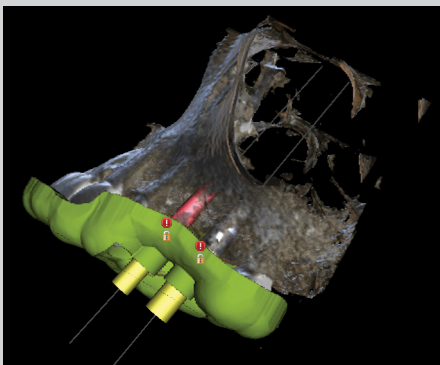
We used two-dimensional radiographs and gypsum stone casts of the patient to treatment plan our ideal implant position and angulation for the proposed dental implant surgical placement.

With the introduction of 3-dimensional imaging such as Cone Beam Computed Tomography (CBCT), dental implant planning software, the ability to import 3-D surface data, and additive manufacturing, we have much more diagnostic information allowing us to become more efficient and accurate than ever before in surgical guide fabrication. The prosthodontist provides the laboratory with all of the diagnostic information for importing into the software.

The process of fabricating a computer planned and manufactured implant surgical guide requires the following laboratory steps:

Importing Diagnostic Information

1. DICOM (Digital Imaging and Communications in Medicine) data from the CBCT is imported into the implant planning software (Figure 1).
2. The 3D surface data of the patient's existing dentition is imported if partially dentate, and the guide is planned to be tooth-supported. This information can be obtained by an optical scan intra-orally or by scanning a cast or impression. The file is saved and imported into the software in a .STL format.
3. Information regarding the proposed restoration also needs to be imported into the software. This can be achieved with a "digital wax-up" or a "traditional wax-up" that is digitally scanned and also saved in a .STL format and imported into the software.



- If the patient is completely edentulous, a dual-scan protocol is utilized. The denture(s) with fiducial markers is/are scanned individually and with the patient wearing the denture(s).
- The DICOM data from the CBCT, the 3D surface data of both the patient and the wax-pattern or dentures need to be “registered” or aligned to be congruent with one another.

Implant Position Planning

Using the diagnostic wax pattern, a certified dental technician (CDT) is able to determine the most accurate implant position to support the definitive restoration.

The prosthodontist will be provided with a saved copy of the proposed plan with all of the data imported to review the proposal (Figure 2). The prosthodontist can review the plan and, if needed, make any necessary changes to the proposed plan. When the final plan is approved, the CDT can proceed with guide fabrication.

Guide Fabrication

Following approval by the prosthodontist, the plan is “locked” to prevent any further changes. There are three types of surgical guides that can be provided. We can fabricate a tooth-supported guide, a tissue-supported guide (for an edentulous patient), or a bone-supported guide to be used after a surgical flap has been reflected to expose the underlying bone. Each of these guides requires a unique approach to guide fabrication.



Fig. 2 (Above): Virtual designing and planning team.

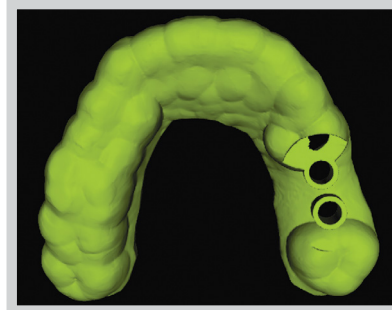


Fig. 3 (Left): Virtual image of a surgical guide.

If a **tooth supported guide** (Figure 3) is going to be fabricated, the CDT will need to indicate in the software to fabricate the guide on the .STL surface data of the imported diagnostic cast.

If a **tissue supported guide** is going to be fabricated, the CDT will need to indicate in the software the need for planning for guide ‘tubes’ to be placed later in a duplicate denture made from the information previously imported. A duplicate denture is then printed via additive manufacturing to fabricate the surgical guide.

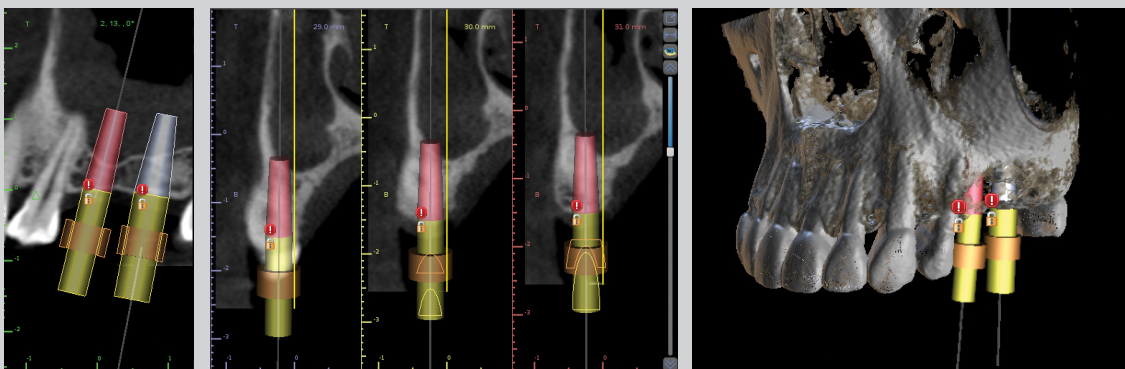


Fig.1: Virtual planning for ideal implant placement.

A **bone supported guide** will require a process known as “segmentation” to create a surface model from the DICOM data. This surface model will essentially be a digital cast of the bone and will be used like the diagnostic cast in the tooth supported guide only now to fabricate the bone-supported surgical guide. These guides can be extremely accurate and stable like the tooth-supported guides.

The outline of the surgical guide is indicated in the software, guide tubes are then placed at the planned implant position and off-set for the implants to be placed, and a digital representation of the surgical guide is planned. Patient identifiers can be added to the guide and the guide exported out of the implant planning software as a .STL file ready for additive manufacturing.

The .STL file is then imported into the additive manufacturing software and fabricated. After the guides




Fig. 4: Mr. Galapir in his virtual domain.

have been fabricated, they are cleaned and prepared for insertion of the metal guide tubes and returned to the prosthodontist for evaluation and prepared for surgery. ■

PROSTHODONTIST STRONG

400K+ TOTAL MEDPRO CASES HANDLED

95% DENTAL TRIAL WIN RATE NATIONALLY

A++ A.M. BEST FINANCIAL STRENGTH RATING

BERKSHIRE HATHAWAY COMPANY

115+ YEARS OF SERVICE

82% OF ALL DENTAL CLAIMS CLOSED WITHOUT PAYMENT

FIND OUT WHY MORE PROSTHODONTISTS ARE MOVING THEIR MALPRACTICE COVERAGE TO MEDPRO'S PROSTHO PREFERRED PROGRAM. WE THINK YOU'LL LIKE WHAT YOU SEE.

Why MedPro?

- Dental Specialty Advisory Board: National dental leaders influencing every area of our business.
- Pure Consent to Settle: At MedPro, no case will ever be settled without your approval.
- Policy Options: Including occurrence, claims-made, and convertible claims-made.
- Value: Get all the advantages MedPro offers for less than you may think.
- Strength: The #1 dental malpractice insurance carrier.

The professional liability program for prosthodontists.

Treloar & Heisel, Inc. • Visit www.treloaronline.com • Call (800) 345-6040



Treloar & Heisel

FINANCIAL SERVICES FOR THE DENTAL AND MEDICAL PROFESSIONAL

PROSTHO Preferred
a MedPro/Berkshire Hathaway program

Ready to lead

Carl F. Driscoll,
DMD, FACP
ACP President

As spring arrives, it marks the rejuvenation of life as temperatures rise and flowers bloom. It is no different in prosthodontics, where digital dentistry has erupted onto the scene with new and improved treatment options.

Starting with the diagnostic capabilities of digital radiology, especially cone beam computed tomography (CBCT), digital dentistry allows us to plan our prostheses (including implants) from start to finish. Optical scanning impressions, CAD/CAM, milling, and 3D printing continue to improve. For a lot of prosthodontists, myself included, it's a different world than the one we entered after residency. But that doesn't mean any of us have to get left behind.

As the organization that represents the specialty of prosthodontics, the ACP is taking steps to ensure that our members are prepared for the emergence of digital dentistry in clinical practice. Through these efforts, we are working to position prosthodontists as the leaders in this technology within organized dentistry.

2016 started with a fantastic Digital Dentistry Symposium in Chicago, which was sold out several weeks in advance. Plans are already in the works for more courses on this topic, which will be accessible to practitioners of any experience level who want to know how to put this stuff to work. Be certain to sign up early to guarantee a seat.

With the support of a \$1.25 million grant from Henry Schein, our highly talented task force is working to develop an educational platform that can be delivered to the dental schools. This platform will lay the foundation for the way we practice for years to come. The Spring Educators Conference devoted an entire day to the subject in April, as program directors and



undergraduate educators converged on Chicago to increase their knowledge and learn the best way to integrate digital dentistry into their schools.

Of course, the Annual Session (Oct. 5-8) is the single best opportunity to get up to date on the latest in technology and its practical application. On Thursday morning, the scientific program will focus on “Digital Frontiers: Latest Breakthroughs”, and speakers throughout the rest of the meeting will show how this technology is being used in patient care. We guarantee great presentations, perfect weather, and an outstanding time along the beautiful shoreline of San Diego.

We know that digital technology will bring dramatic changes to dentistry – it's a matter of time. Patient outcomes are being elevated and so are patient expectations. Your fellow specialists and referral sources will be looking to you for leadership. As a member of the College, you will be ready. ■

Harnessing the power of digital technology

Robert Gottlander, DDS
Chief Marketing Officer
Henry Schein Global Dental Group

For decades, digital technology has been used in many different ways by dental professionals. In dental practices today, digitization plays a key role in patient record keeping, treatment planning, imaging, fixed and removable prosthetics, and submission of insurance claims.

We also know that digital technology is changing our lives. As with any new technology in any industry, its adoption can sometimes cause frustration based on its often disruptive characteristics. To help overcome these challenges in the dental practice or laboratory, it is helpful to focus on what the technology can do to improve the efficiency and effectiveness of each stage of the practice workflow and the quality of patient care. The development of new materials, combined with advances in user-friendly digital solutions has led to an increase in the speed of digitization and its adoption, especially by dental laboratories. While dental laboratories have been faster to adopt CAD/CAM technology, more and more dental practices are integrating digital solutions at an increasingly faster pace.

New digital dental technology can greatly enhance the practice workflow and patient experience, but its success hinges on the interoperability between the digitally driven products within the workflow. Critical to this interoperability is the practice management software - the hub that connects all things digital in a practice or laboratory. This interoperability extends to communications between the practice and dental laboratory, to communications within the dental team, and to current and prospective patients in the community.

In a world driven by innovation, new products and technology solutions are launched at a rapid pace, and it is not always easy to determine how a new

solution might best be integrated into a practice or laboratory, and importantly, if an investment in a new technology is worthwhile. Most practitioners have made the decision to incorporate digital dentistry into their practice or laboratory, but some are still asking themselves, “When is the right time for me?”

Henry Schein ConnectDental is an innovation created for this very reason—to help practitioners comfortably enter or expand further into the world of digital dentistry not by just looking at the individual technology and products available on the market today, but by uncovering how these solutions can best be integrated into the practice or laboratory, and seeing how it can enhance the care they provide to patients.

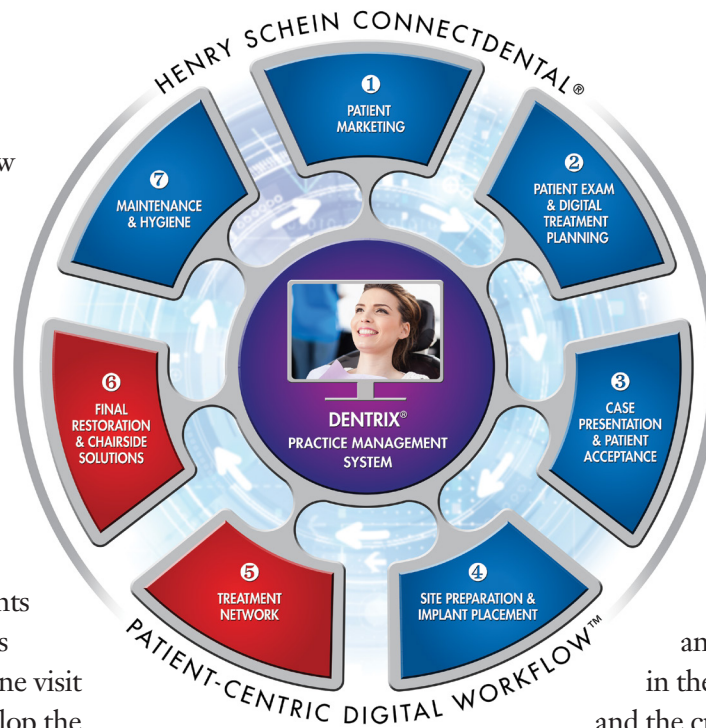
Henry Schein ConnectDental offers an opportunity for practitioners to explore the industry’s broadest array of “open” solutions required to bring any practice or laboratory into today’s digital age. From the latest digital innovations with intraoral scanners, milling and printing devices and materials, to cone beam 3D imaging, practice management systems, and a wide selection of digital dental laboratory solutions, Henry Schein ConnectDental also demonstrates how they are successfully integrated into a patient-centric workflow. All backed by the critical support, services, and education needed for success.

As a trusted advisor to its customers, Henry Schein places great emphasis on its early discussions with practitioners to ensure their specific needs are met.

It's also important to review the practice so that its computer network, compressors, and other equipment fulfill the necessary requirements; this analysis is also a part of ConnectDental. We also include the very important integration of the technology into the office. Scheduling of patients and how to train the staff is critical when integrating one visit solutions, not only to develop the optimal workflow, but also to maintain it over time. Support and ongoing education is imperative to keep technology not only functioning but also to optimize its usage. More and more solutions are incorporating the use of CAD/CAM. Restorations might be the obvious use of a CAD/CAM system, but orthodontics, planning for the surgical placement of dental implants, and subsequent restorations are also areas where CAD/CAM is used today.

Underscoring the importance of education, Henry Schein recently announced its partnership with the ACPEF through a commitment of \$1.25 million to fund the ACP's program for the development of a new curriculum that incorporates CAD/CAM solutions into the dental school curriculum. Together with its valued supplier partners, Planmeca, 3Shape, Glidewell, BioHorizons, and CAMLOG, Henry Schein is committed to supporting education and training needed to effectively apply digital solutions into the future work of practitioners.

Looking forward, we will seek new materials that will be used for digital efficiencies and improved



patient experiences. New production technologies including additive methods like printing will be optimized. New milling techniques such as laser milling will also be presented. Intraoral scanners are faster and easier to use today than ever before, and they can play a big role in the diagnosis of the patient and the creation of the patient

record. Development of new technology is taking place as in many other areas of society. A laptop of today is faster than the laptop from last year. However, we will still implement today's best offering as it works well and helps us in our day to day work—it is the same with CAD/CAM, it makes a difference in the practice.

The rapid growth of digital dentistry will continue to change the industry. In its dynamic, transformational role, digital technology has touched every aspect of the dental field by offering professionals communication, management, and clinical and fabrication options never before possible. Henry Schein is committed to helping practitioners successfully navigate through the digital journey with trusted digital solutions that a practice or laboratory can rely on. ■



Supporting innovative research

The ACP Education Foundation partners with GlaxoSmithKline Consumer Healthcare to sponsor the Prosthodontist Innovator Award. The goals of this research award are to advance the understanding of prosthodontics related biological and/or materials systems, human behavior, cost and care delivery, as well as economic modeling and quality of life investigations.

The ACPEF interviewed past recipients Dr. Cortino Sukotjo (2011) and Dr. Ghadeer Thalji (2013) to find out how the award has impacted their careers.

What did it mean for your project to receive the award?

Dr. Sukotjo: I was very honored and humbled. I was able to utilize the funds to answer research questions and extrapolate to the science at large. This award had a significant impact on my research career, as well as my academic promotion and enhancement. It has also enabled collaboration across continents and other disciplines such as chemical engineering and mechanical engineering.

Dr. Thalji: It brought me great pleasure to feel supported by my ACP colleagues. The major focus of this grant was on investigating the effects of the presence of the pathophysiological state of type 2 diabetes in obese individuals on the modulation of gene transcription related to acquisition of M2 macrophage properties in implant adherent cells in an oral implant integration model compared with non-obese non-diabetic individuals. Elucidation of the role of M2 macrophage in bone regeneration is essential for our understanding of bone healing and also advances strategies to accelerate bone repair.

What would you say to someone who is considering whether to apply for the award?

Dr. Sukotjo: Like other grant applications, the Prosthodontist Innovator Award application is a rigorous process, which requires a very high standard of work, dedication, and commitment.

Dr. Thalji: As a director and mentor for graduate residents, I feel that our mission in advancing our specialty with new innovations through research is only made easier by the continuous support of the ACP Education Foundation for its young members. I strongly encourage other members to apply for this award.



Dr. Cortino Sukotjo and Dr. Ghadeer Thalji

What is the main focus of your work today?

Dr. Sukotjo: I was recently promoted to tenured associate professor at the University of Illinois at Chicago. My current research focus is implant corrosion / tribocorrosion and the use of nanotechnology to modify implant surfaces.

I would like to express my appreciation for this prestigious award. I would also like to express my gratitude for the support from my research team, and my department chair, Dr. Campbell. Without their support, I would not have come this far.

Dr. Thalji: I currently serve as the graduate program director in prosthodontics at University of Iowa. My various roles, including clinical prosthodontics and teaching, are broadened by my involvement in clinical translational research.


A synergy of art and science renders the field of prosthodontics one in which demanding technical skill must be partnered with thoughtful foresight. Advances in delivering improved patient care results are only made possible through research. Research is a very critical aspect in everything we do from both the biological perspective and biomechanical behavioral aspect of the materials we use. ■



Prosthodontic Review Course

The Role of Implants and Conventional
Prosthodontics in Today's Practice

Washington, DC
Sept. 9-10, 2016



“Open and thoughtful discussion of the most recent innovations and complications that we encounter on a regular basis...an amazing review course.” – *Lynn Kiangsoontra, DMD*

COURSE DIRECTOR

Steven J. Sadowsky, DDS, FACP

ACP | AMERICAN COLLEGE OF
PROSTHODONTISTS
Your smile. Our specialty.®

Register at Prosthodontics.org

The intersection of art and technology

John R. Agar,
DDS, MA, FACP,
Program Chair

Arthur C. Clarke said that any sufficiently advanced technology is indistinguishable from magic. Some might say we have reached that point in dentistry. Technology is revealing new ways to do things we have been doing for years, and it is changing what is possible in health, function, and beauty.

Without advanced training, this level of patient care might appear to be magic. But as prosthodontists, it's our specialty.

The 46th Annual Session of the American College of Prosthodontists is bound for San Diego, Oct. 5-8. Our theme is "Prosthodontics: The Intersection of Art & Technology". This meeting is designed to keep you up to date with the rapid changes in how patient care is being planned and delivered today – and what's coming around the bend tomorrow.

On Thursday morning, we'll explore **Digital Frontiers**. These are the very latest breakthroughs, direct from the forefront of clinical practice. You'll see how technology can improve esthetics through superior accuracy and control in the transition zone. Speakers will discuss the capabilities and the limitations of CAD/CAM, and present strategies you can use to save valuable time in the clinic, improve patient acceptance, and deliver a beautiful, highly functional prosthesis every time.

The mantra on Thursday afternoon is **Outcome Dictates Treatment**. As prosthodontists, we don't leave anything to chance. We examine the science and we think ahead, about where the patient is now and where they will be. These speakers will show you how to see





the final result before providing care, from the long-term survival rates of the latest all-ceramic materials to the link between edentulism and health problems such as cardiovascular disease, diabetes, and obesity.

In both sessions, the presenters will take a frank look at the current applications and capabilities of 3D printers in clinical practice, including the printing of custom, patient-specific implants and the world's first 3D-printed mandible replacement.

Overlooking San Diego Bay, the Grand Hyatt has been newly renovated since the ACP's last visit and it is an incredible venue. In addition to some of the finest meeting space we've ever seen, the rooftop pool is a gem, and the downtown location offers easy access to the popular Gaslamp Quarter, the world famous San Diego Zoo, the USS Midway aircraft carrier, and much more.

In the next issue, we'll look at the Friday scientific session, as well as the opportunities to extend the impact of your registration with sessions on TMJ, dental technology, and transitioning into private practice.

Bring your friends, family, and referral sources. We're going to have a great time in San Diego! ■



Thursday Scientific Session

Digital Frontiers: Latest Breakthroughs

Implant Esthetics: Working the Transition Zone

Frank L. Higginbottom, DDS

Life Hacks: Intraoral Optical Scanning and 3D Printing Right in Your Practice

Michael D. Scherer, DMD, MS, FACP

Beyond the Limitations of CAD/CAM

Junhyouk Shin, DDS, MS

100% Esthetics: Digital Components for the Practice

Enrico Steger, MDT

Digital Dentistry: Applications and Potential Pitfalls

Radi M. Masri, DDS, MS, PhD, FACP

Digital Symbiosis: Reimagining the Future of Restorative Dentistry

Lee Culp, CDT

Outcome Dictates Treatment

Metal-Ceramic Restorations in the Esthetic Zone:

Is It a Serious Consideration?

Robert R. Winter, DDS

Interdisciplinary Solutions for Esthetic Periodontal Prosthodontic Rehabilitations

Kenneth A. Malament, DDS, MScD, FACP

Facts & Fallacies: The Prosthodontic Dilemma

Harold W. Preiskel, MDS, MSc, FDS, RCS

Edentulism and Co-Morbid Diseases: Are They Related?

David A. Felton, DDS, MS, FACP

3D Printed Cranio-Maxillofacial Implants and Prostheses: A New Era!

Jules Poukens, MD, DMD

Sharry Awards: Call for Abstracts

The 2016 John J. Sharry Prosthodontic Research Competition will be held on Oct. 7 at the ACP Annual Session in San Diego. Sponsored by the ACP Education Foundation, the Prosthodontic Research Competition seeks original research in prosthodontics by students and residents. Abstracts are due by May 23. Visit acp46.com for submission guidelines.

Spokespersons Network Scholarships: Apply Now



The ACP will award up to 5 scholarships to recent graduates (4 new practitioners and 1 academic prosthodontist) to attend the 2016 Spokespersons Network Training on Oct. 5-6 in San Diego. Apply online by June 1 as demand exceeds capacity for this popular course.

Participants will receive professional media training, public relations skills, a hot topic video, and headshots. Without the scholarship, the fee is \$750 (for training with a market value of \$7,500-\$10,000) and the class is limited to 15 participants.

For more information and to apply, visit Prosthodontics.org/pr/spokespersons.

In the Latest Journal of Prosthodontics

In the current issue of the *Journal of Prosthodontics*, Drs. Ketu P. Lincoln, Albert Y. T. Sun, Thomas J. Prihoda, and Alan J. Sutton compare the accuracy of facial models fabricated using facial moulage impression methods to the three-dimensional printed (3DP) fabrication methods using soft tissue images obtained from cone beam computed tomography (CBCT) and 3D stereophotogrammetry (3D-SPG) scans.



The use of 3D-SPG has a great potential for use in the military. The number of facial injuries sustained by military forces during this nation's recent wars has risen dramatically. This is primarily because the survival rate has increased due to improvement in body armor, battlefield medicine, tactically placed medical units, and quick evacuation tactics. Soldiers with severe facial injuries are surviving, when they may not have survived in past wars.

Military members suffering from head/face/neck injuries (HFNI) present to medical and dental clinics with facial dysmorphologies, such as missing ears, requiring facial prostheses. In the past, these patients required creation of models of the area of deformity by using previous 2D photographs, an impression of family member anatomical replicas, or a prosthesis fabricated by an anaplastologist to replicate the lost tissue. Now, with 3D-SPG and CBCT images, recreation of missing tissue can be accomplished by banked images, images of family members, or even custom-created anatomic forms.

Furthermore, images of military members could be obtained and archived prior to entering a military conflict. If the military member should sustain any HFNI, then the archive image can be referenced to create a model in the fabrication of a more accurate facial prosthesis.

This study found that 3DP models fabricated using 3D-SPG showed a statistical difference in comparison to the models fabricated using the traditional method of facial moulage and 3DP models fabricated from CBCT imaging; 3DP models fabricated using 3D-SPG were less accurate than the control facial model and models fabricated using facial moulage and CBCT imaging techniques; and models fabricated using CBCT imaging and facial moulage showed no statistical difference and proved to be accurate in comparison to the control phantom model.

This research won third prize at the 2015 John J. Sharry Research Competition, presented at the 2015 ACP Annual Session.

Lincoln KP, Sun AYT, Prihoda TJ, et al: Comparative accuracy of facial models fabricated using traditional and 3D imaging techniques. J Prosthodont doi: 10.1111/jopr.12358



The Power of Digital Design

Held in Chicago on Feb. 22-23, the ACP's second digital dentistry symposium hosted a sold-out crowd! The symposium showcased state-of-the-art digital solutions for the treatment of restorative patients, including best practices and actual clinical workflows.

Attendees included prosthodontists, dental technicians, and general dentists from all over the world. "The novice and experienced attendees learned from each other and broadened their horizons. The camaraderie was palpable and the transfer of knowledge was inspiring," said Dr. Carl F. Driscoll, ACP President.

Thanks to Biodenta, DENTSPLY Implants North America, Henry Schein, Ivoclar Vivadent, Nobel Biocare, and Straumann for their sponsorship of the symposium.

ASDA Annual Session

Dr. Brian Aguirre, 2nd year resident, and Dr. Druthil Belur, 1st year resident, Texas A&M University - Baylor College of Dentistry, represented the ACP at the 2016 Annual Session of the American



Student Dental Association, which brought more than 600 dental students to Dallas.

This conference is a source of personal and professional development: career planning, business and financial leadership, advocacy, professional issues, chapter

leadership, and management. This meeting is the official gathering of ASDA's House of Delegates where policies are set and leaders are elected.

Students that dropped by the booth learned about residency programs, careers in prosthodontics, and the benefits of ACP student membership.

Welcome New Members

January – March 2016

Reinstated International Fellows

Dr. Abdulrahman R. Alhasanyah
Dr. Yi-Hua Niu

New Global Alliance Affiliate

Dr. Mohammed Ibrahim
Abuanzeh

Reinstated Members

Dr. Lawrence E. Brecht
Dr. Angela J. Mumm
Dr. Sang E. Park
Dr. John W. Payne, II
Dr. Ruth S. Rojas

Reinstated International Member

Dr. Catherine L. Pham

New Predoctoral Alliance Affiliates

Ms. Sadaf Assadi
Ms. Aaema Athar
Ms. Kelly Chuang
Mr. Amro Elkhatieb
Mr. Olivier Éthier-Da Costa
Ms. Aurore Fonderflick
Ms. Loren N. Genetti
Ms. Shada H. Ghnaim
Mr. Victor Y. Lee
Mr. Abdelrahman Mohamed
Ms. Sable A. Muntean
Ms. Hwan Hee Park
Mr. James P. Pizzo
Ms. Sandrine Shooner-Brassard
Ms. Jasmine J. Silas
Ms. Jie Sun
Ms. Edidiong N. Umoh
Ms. Mariam C. Vonderheide

New Resident/Graduate Student Members

Dr. Mohanad A. Abumelha
Dr. Fadwa Alhrthy
Dr. Dong-Jin Shin

Upcoming Events

Prosthodontic
Review Course
Washington, DC
Sept. 9-10, 2016
Prosthodontics.org

.....
46th Annual Session
San Diego
Oct. 5-8, 2016
acp46.com

Job Opportunities

California (Palm Desert) -

Board Certified Prosthodontist is seeking a motivated associate to join state of the art modern office. Well-established fee for service practice. Excellent opportunity for enthusiastic outgoing Prosthodontist who also enjoys outdoors lifestyle, resort like community of tennis, golf, hiking, biking, and swimming. Associate leading to equity partnership. Email cwcdent@aol.com.



Colorado (Denver) -

Prosthodontic practice seeking associate with potential for equal partnership. Established practice with increasing prosthodontic referral base in rapidly growing area. Current technology includes Galileos CT, Cerec CAD/CAM, EMR, digital radiography. New office to be completed in Fall 2016 to include in-house lecture facility. Send introductory letter and CV to taylorgoggins@gmail.com.



AESTHETIC & IMPLANT DENTISTRY OF ATLANTA

Georgia (Atlanta) -

Opportunity to join an established comprehensive prosthodontic practice. Beautiful and modern center in the heart of Metro Atlanta designed for continued expansion and growth. Eager individual who understands the dynamics of "building a practice." Engaging with patients, relationships with referring doctors,

actively involved in dental organizations and study clubs, community involvement and excellence of care is paramount to consideration. Professional staff, 6 ops, offering fixed, implant and removal prosthodontics as well as comprehensive dental care. www.davidzelbydds.com Email CV and Cover Letter: zoe.zelby@gmail.com Call: 678-637-1882

Illinois (Skokie) -


Outstanding partnership opportunity for a talented, caring, energetic, detailed-oriented Prosthodontist with excellent verbal and interpersonal skills. Beautiful office with exceptional laboratory support. Fee for service practice with emphasis in Fixed Prosthodontics, Implants and Restorative. Send CV to: oralrehab1@gmail.com.

Maryland (Baltimore) -

Seeking a highly motivated prosthodontist for a modern private practice located on the campus of a hospital. General prosthodontics with a maxillofacial component. Patient-centered with high quality care. Tremendous long-term opportunity for the right individual. Please email resume and contact information to info@marylandprotho.com.

Michigan (Oakland County) -

Practice opportunity leading to full partnership in a well-established multi-practitioner prosthodontic practice located in Oakland County, Michigan. Fee for service practice: fixed, removable, implant prosthodontics and maxillofacial prosthetics. Full staff including two technicians and 7 operatories. American Board of Prosthodontics certification preferred. Confidential email inquiries to: PicMichigan@comcast.net.



Ohio (Columbus Area) -

Highly productive Prosthodontic practice that has been in business for over forty years. Large patient base that is both referral base and has a general dental component with a fully integrated hygiene department. Practice is state of the art, including the following:

- In-house fixed laboratory technician
- In-house removable technician
- i-CAT flex cone beam technology
- Itero Intraoral Scanner
- Digital radiography
- In-house lecture facility
- Fully integrated study club, including a dedicated website

The practice is heavily involved in continuing education and providing very high quality care to patients in the Greater Columbus, Ohio area. The practice will be a partnership opportunity with an immediate opportunity to buy in. Prosthodontist is desired, but not required. For further information, please call 614-885-7742 and ask for Tari.

Tennessee (Memphis) -

Partnership opportunity for a Prosthodontist at the Dental Implant Aesthetic Center in Memphis, TN. Send resume to cwschulter@dentalimplantac.com. Our web page is www.dentalimplantac.com for information on the practice.

Texas (Dallas-Ft. Worth) -

Private practice Prosthodontic group seeks ambitious, strong work ethic, high quality outcomes-oriented prosthodontist. Small, fee for service practice with two doctors, one retiring soon. Great opportunity in one of the strongest economies in the country. Email david_mcfadden_dmd@yahoo.com.

Texas (University of Texas Health Science Center) -

The University of Texas Health Science Center at Houston, School of Dentistry seeks applicants for a part-time (0.6 FTE) faculty position in the Department of Restorative Dentistry and Prosthodontics. The appointment is expected to be at the Clinical Assistant Professor level. The position is available January 01, 2016. Applicants must have a DDS/DMD/DBS degree with prior teaching and/or private practice experience. Advanced training in Prosthodontics recognized by the Commission on Dental Accreditation of the American Dental Association or graduate training from an accredited dental institution is required as well as be eligible for licensure in the state of Texas. Board certification by the American Board of Prosthodontics is preferred.

Responsibilities of the position are to provide lectures, pre-clinical and clinical instruction in Restorative Dentistry and Prosthodontics to undergraduate dental students and Prosthodontics residents, to conduct research, and to provide service to the university such as serving on standing and ad-hoc dental school committees.

Academic rank and salary are commensurate with qualifications and experience. The School of Dentistry is located in the heart of the Texas Medical Center which offers significant resources and important opportunities for collaboration and advanced training. The School of Dentistry is one of six schools in the most comprehensive health science center in Texas. UT Health is an equal opportunity employer and a non-smoking environment. Women, minorities, disabled, and veterans are encouraged to apply. This is a security sensitive position and thereby subject to Texas Education Code # 51.215. A background check will be required for the final candidates.

Please submit application and supporting documents (CV, statement of teaching and research interests, and names and addresses of three references) must be submitted online at: <https://jobs.uth.tmc.edu/applicants/Central?quickFind=108559>

Requisition #: 161149

Applications will be accepted until positions are filled.

Texas (University of Texas Health Science Center) -

The University of Texas Health Science Center at Houston, School of Dentistry seeks applicants for a part-time (0.6 FTE) faculty position in the Department of Restorative Dentistry and Prosthodontics. The appointment is expected to be at the Clinical Assistant Professor level. The position is available January 01, 2016. The applicant must have a dental degree recognized by the Commission on Dental Accreditation of the American Dental Association or graduate training from an accredited dental institution as well as be eligible for licensure in the state of Texas.

Responsibilities of the position are to provide lectures, pre-clinical and clinical instruction in Restorative Dentistry and Prosthodontics to undergraduate dental students, to conduct research, and to provide service to the university such as serving on standing and ad-hoc dental school committees.

Academic rank and salary are commensurate with qualifications and experience. The School of Dentistry is located in the heart of the Texas Medical Center which offers significant resources and important opportunities for collaboration and advanced training. The School of Dentistry is one of six schools in the most comprehensive health science center in Texas. UT Health is an equal opportunity employer and a non-smoking environment. Women, minorities, disabled, and veterans are encouraged to apply. This is a security sensitive position and thereby subject to Texas Education Code # 51.215. A background check will be required for the final candidates.

Please submit application and supporting documents (CV, statement of teaching and research interests, and names and addresses of three references) must be submitted online at: <https://jobs.uth.tmc.edu/applicants/Central?quickFind=108530>

Requisition #: 161144

Applications will be accepted until positions are filled.

1st Advantage DENTAL

Vermont (Brattleboro) -

1st Advantage Dental is an established multi-specialty group practice with locations in New York, Massachusetts, and Vermont. Whether it's the Capital District of New York or the beautiful Pioneer Valley of Vermont, we are committed to providing the best possible oral health care to our patients. We are interested in speaking with candidates interested in joining our Brattleboro, VT practice. Send CV & Cover Letter to kateanderson@amdpi.com.

Practices for Sale

California (Napa County) -

Napa County: General adult practice ideal for a prosthodontist with an emphasis on complex restorative, cosmetic and implant treatment. This office is state of the art and utilizes CEREC and 3-D conebeam technology. The office averages three days per week with tremendous upside potential as many endodontic, implant placement and oral surgery cases are referred to local specialists. Annual revenues average \$600,000 with a net income of \$250,000. Interested prospects should send a cover letter and current CV by email to molinelli@aol.com or call 650-347-5346.

California (Napa) -

Prosthodontic practice est in 1985 occupies 1712 sq ft with 4 fully equipped operatories, 3D CBCT and removable prosthetics lab. Collections just under 1 million on a 3 day work week with 2 days of hygiene per week. Contact Tim Giroux at 530-218-8968 or wps@succeed.net.

California (Palm Desert) -

State of the art specialty practice established in 1992. Digital pano, Dentrax, 5 ops, lecture room, ADEC equipment, 3,000 sq ft, great location. Prosthodontist that places implants best candidate. Motivated seller, serious inquiries only. \$800K collections. Email: golfinthedesert@gmail.com.

Massachusetts (Andover) -

Small, but lucrative prosthodontic practice for sale in Massachusetts. Produce \$350-400K/year on 2 days per week. I teach other days at local dental school. Located in prestigious Andover-North Andover area located 25 miles north of Boston. A perfect area to settle and practice your specialty. The ocean, mountains, and a great world class city nearby. Please contact louisrissin@gmail.com or 978-686-2620.

New England (Boston Area) -

Profitable high end fee for service practice available in premium location (an hour outside Boston). This well respected practitioner with loyal patient following and steady stream of referrals from satisfied patients. Owner is willing to help new buyer transition if desired. Production per hour consistently exceeding \$1,400 on 18-24 hours per week. Call Jim Kasper Associates, LLC at 603-355-2260.

New Mexico (Albuquerque) -

Boarded prosthodontist with established practice is seeking a motivated clinician to assume his longstanding practice. Doctor must be comfortable with fixed, removable and maxillofacial prosthetics. The 1700 sq. ft. clinic is attached to a 1300 sq. ft. dental laboratory with three in-house technicians. Collections exceed \$1.2 million annually. The office is the only source of maxillofacial prosthodontic care in the state and receives full fees for maxillofacial prosthetic services. The clinic is located near hospitals and the University of New Mexico.

Applicant should be a board qualified or a boarded prosthodontist. A Spanish speaking individual is desirable.

Albuquerque is a modern active city in the Southwest. Outdoor and cultural activities are abundant with a mild four season climate.

Contact Dr. Stephen Wagner at 505.401.8200 and bigjawbone@mac.com.

Texas (Austin) -

Established, profitable, high percentage net practice is available for buy in or buy out. The practice is primarily oriented in implant dentistry, fixed, and removable prosthodontics. 5 fully equipped operatories, 3D CBCT and fully equipped lab. In case of buy out owner will stay on part-time as needed to facilitate the transition. Contact austindentist5@yahoo.com.

Texas (Dallas-Ft. Worth) -

Dallas Fort Worth traditional fee for service prosthodontist is seeking a qualified successor to assume this exceptional practice. 5 operator free standing facility. Trios 3 Pod-Pen system, Cadiax4, ILase, digital imaging. Seller desires Board Certified or Board Eligible practitioner wanting a single location, community oriented, relationship style practice. Seller will provide transition as needed. Ideal candidate will have private practice experience. Send CV and introductory letter to Info@lewishealth.com.

Utah (Salt Lake City) -

Salt Lake City Prosthodontic practice and office space available for immediate purchase and transition. Practice is primarily oriented in implant prosthodontics, fixed, and removable prosthodontics. 30 year established practice with good referral sources. 3 ops with room for expansion. 1755 sq. ft. Doctor can stay for transition and to introduce referral sources, if desired. Good opportunity and very reasonably priced at \$300,000, which includes the building and all equipment. Contact at: 801-261-5250 or 801-450-8057. Send CV or resume to Linda Montgomery, 2256 Cottonwood Ln. Salt Lake City, UT 84117 or leefamily@utahisp.com. Would like to retire as soon as possible.

Washington (Seattle) -

OPPORTUNITY TO LIVE AND PRACTICE IN THE BEAUTIFUL PACIFIC NORTHWEST. Well established and mature prosthodontic specialty practice with exceptional reputation for sale in the Greater Seattle area. Procedures provided by the seller include crown and bridge, implants and complete and partial dentures. Fee for service practice with no contracted insurance. Outstanding, established referral base. Annual collections are consistently over \$2 million per year with very strong cash flow. Well managed practice with a high percentage net. Building is in a great location with plenty of parking and visibility. Seller could eventually sell the building to the buyer. Owner would stay on 1-2 days per week for up to a year or more to ensure a smooth transition and to introduce referrals sources.

Contact: Buck Reasor, DMD

Reasor Professional Dental Services

503-680-4366

info@reasorprofessional dental.com

Washington (South Puget Sound) -

Come live, play, and work in the beautiful Pacific Northwest! Immaculate, well established and respected full-range prosthodontic practice to include implant surgery. The office features four fully equipped operatories featuring full computerization and digital radiography. Two operatories are also equipped with surgical microscopes. The practice features an in-house state of the art fixed/removable dental laboratory and a new cone beam CT/digital panoramic scanner. Second floor suite in a modern medical office building with expansive windows throughout. The practice has a strong referral base from throughout SW Washington and has easy access from Interstate-5. Practice collections nearly \$1.4M with fee for service only. Long term dedicated staff. Owner will stay on part-time as needed to facilitate the transition. For more details and information please contact: Jennifer Paine at (425) 216-1612 or email Jennifer@cpa4dds.com.



Follow nature's contour

OsseoSpeed™ Profile EV —A unique implant specifically designed for sloped ridges

OsseoSpeed Profile EV is specially designed for efficient use of existing bone in sloped ridge situations.

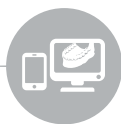- Provides 360 degrees of bone preservation maintaining soft tissue esthetics
- Can help to reduce the need for bone augmentation
- Components designed to allow for accurate identification of the implant position throughout the treatment process

OsseoSpeed Profile EV is an integral part of the new ASTRA TECH Implant System™ EV and is supported by the unique ASTRA TECH Implant System BioManagement Complex.

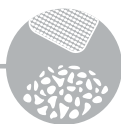
For more information visit
www.jointheev.com



STEPPS™



SIMPLANT™



SYMBIOS™



ANKYLOS™



ATLANTIS™

**ASTRA TECH
IMPLANT SYSTEM**

XiVE™

INTRODUCING

AccuDent® XD

Alginate Impression System



A beautiful smile makes
a great impression...

...but It takes a great impression to make a beautiful smile.

*Introducing AccuDent XD, the next generation
alginate impression System.*

- **Dual-phase alginate materials** for more accuracy and precision than traditional alginates
- **Thermoplastic heat moldable impression trays** to accommodate all arch forms
- **Low cost and fast set time** for optimum productivity

100% CUSTOMER SATISFACTION
GUARANTEED!



ivoclarvivadent.com

For more information, call us at 1-800-533-6825 in the U.S., 1-800-263-8182 in Canada.
©2015 Ivoclar Vivadent, Inc. Ivoclar Vivadent and AccuDent are trademarks of Ivoclar Vivadent, Inc.


ivoclar
vivadent[®]
passion vision innovation