

ACP MESSENGER

Spring 2014

Treatments for Stronger Bones
Grinding Teeth? Talk to a Prosthodontist
Medical/Dental Teamwork

ACP
AMERICAN COLLEGE OF
PROSTHODONTISTS

Your smile.
Our specialty.®

Introducing

Virtual[®] XD *Extra Definition*



Make your first impression your best impression!

Introducing Virtual XD, an advanced vinyl polysiloxane impression system featuring "Extra Definition" wash materials providing:

- **Optimized flow characteristics** for deeper penetration into the sulcus and improved coverage of the preparation.
- **Advanced wetting ability** for precise detail reproduction of both soft and hard tissue.
- **High tear strength** to maintain the integrity of preparation margins and fine detail upon removal of the impression.

Try Virtual XD and see your next case in Extra Definition!
Visit ivoclarvivadent.com/virtual for your **FREE SAMPLE!**

100% CUSTOMER SATISFACTION
GUARANTEED!



ivoclarvivadent.com

Call us toll free at 1.800.533.6825 in the US, 1.800.263.8182 in Canada
©2014 Ivoclar Vivadent, Inc. Virtual is a registered trademark of Ivoclar Vivadent, Inc..

ivoclar
vivadent[®]
passion vision innovation



Throughout my life, I had made investments in my mouth with so many “quick fixes” along the way. Yet no one appeared to get to the root of my problem. That changed when I visited a prosthodontist, who had the expertise to take care of my complex situation. My prosthodontist showed me how oral health is connected to health throughout the body. Now, my husband tells me my smile looks beautiful and natural, and I look and feel great!

In Every Issue

- 6 From the Editor
A Patient-Centered Focus

- 8 In the Office
Treatments for Healthy Bones

- 12 At the Chair
Grinding Teeth? Talk to a Prosthodontist

- 14 Case Presentation
Meeting the Challenges of Ectodermal Dysplasia

- 18 For the Patient
Q&A: Oral Hygiene

- 27 Our Community

- 28 Announcements

- 29 Classified Ads

- 30 Upcoming Events

Featured

- 20 From the ACP Leadership

- 22 Annual Session Preview

- 24 Inside the ACPEF

Editor in Chief

Jacinthe M. Paquette, D.D.S., F.A.C.P.

Associate Editors

Carl F. Driscoll, D.M.D., F.A.C.P.
Frank J. Tuminelli, D.M.D., F.A.C.P.

Editor Emeritus

Lyndon F. Cooper, D.D.S., Ph.D., F.A.C.P.

ACP Board of Directors

John R. Agar, D.D.S., M.A., F.A.C.P., President
Frank J. Tuminelli, D.M.D., F.A.C.P., President-Elect
Carl F. Driscoll, D.M.D., F.A.C.P., Vice President
Susan E. Brackett, D.D.S., M.S., F.A.C.P., Secretary
Julie A. Holloway, D.D.S., M.S., F.A.C.P., Treasurer
Lee M. Jameson, D.D.S., M.S., F.A.C.P., Immediate Past President
Nadim Z. Baba, D.M.D., M.S.D., F.A.C.P., Regional Membership Director - Pacific
Douglas G. Bening, D.D.S., M.S., F.A.C.P., Director, Prosthodontic Practice & Patient Care Division
Lars Bouma, D.D.S., M.S., F.A.C.P., Regional Membership Director - Central
Lino P. Calvani, D.D.S., M.Sc., F.A.C.P., Regional Membership Director - International
Alan B. Carr, D.D.S., M.S., F.A.C.P., Director, Education & Research
Nancy Deal Chandler, R.H.I.A., C.A.E., C.F.R.E., Executive Director
David A. Felton, D.D.S., M.S.D., F.A.C.P., Editor, Journal of Prosthodontics
Lily T. Garcia, D.D.S., M.S., F.A.C.P., Chair, ACP Education Foundation
Gerald T. Grant, D.M.D., M.S., F.A.C.P., Regional Membership Director - Federal Services
David L. Guichet, D.D.S., F.A.C.P., Director, Continuing & Professional Education
Stephen I. Hudis, D.D.S., F.A.C.P., Regional Membership Director - Northeast
Mark C. Hutten, D.D.S., M.S., F.A.C.P., Director, Forum
Paul E. Scruggs, D.D.S., P.A., Regional Membership Director - East
Robert M. Taft, D.D.S., M.S., F.A.C.P., Director, Maxillofacial Prosthetics
Victoria A. Vickers, D.D.S., Director, Public Relations and Communications
Alvin G. Wee, D.D.S., M.S., M.P.H., Regional Membership Director - Rockies/Plains

ACP Central Office Staff

Nancy Deal Chandler, R.H.I.A., C.A.E., C.F.R.E., Executive Director
Carla Baker, M.B.A., C.A.E., Associate Executive Director, Membership Services & Outreach
Carolyn Barth, Director, Media Relations
Mark Heiden, Director, Communications & Marketing
Melissa Kabadian, M.A., C.M.P., Director, Education & Meeting Services
Jack Kanich, Finance & Administration Manager
Justin McDaniel, Administrative Coordinator
Adam Reshan, Membership Services Manager
Lauren Swanson, Communications & Marketing Coordinator
Nathalie Williams, Sections & Governance Manager

Managing Editor

Mark Heiden

Editorial Coordinator

Lauren Swanson

Design

Publications Associates, Inc.

Display Advertising

Gennifer Kelling, M.J. Mrvica Associates, Inc.
Phone: (856) 768-9360
Email: gkelling@mrvica.com

Classified Advertising

Visit the 'Members and Dental Professionals' section at GoToAPro.org to download an insertion form. Email or fax the completed form to Lauren Swanson at lswanson@prosthodontics.org or (312) 573-1257. Classified ads are \$100 for the first 50 words and \$1 for each additional word for ACP members. The non-member rate is \$200 for the first 50 words and \$2 for each additional word. The minimum charge is \$100. Logos are an additional \$50, limited to one per ad and subject to approval. Payment by check, American Express, Visa, or Mastercard is required prior to placement.

The mission of the ACP Messenger is to inform readers about current prosthodontic trends, challenges, and successes. Statements of fact and opinion are the responsibility of the authors alone and do not imply an opinion on the part of the officers or the members of the ACP.

The ACP Messenger annual subscription rate for members is \$45, which is included in membership dues. The U.S. subscription rate for Prosthodontic Forum Organization members is \$55 and \$65 for non-members. Canadian subscribers add \$5 each year; all other non-U.S. subscribers add \$10 each year.

The ACP Messenger (ISSN # 0736-346X) is published four times per year in the winter, spring, summer, and fall by the American College of Prosthodontists:

211 E. Chicago Ave., Suite 1000, Chicago, IL 60611
Phone: (312) 573-1260; Fax: (312) 573-1257
Email: acp@prosthodontics.org
Website: GoToAPro.org

© Copyright 2014 American College of Prosthodontists. All rights reserved. Materials may not be reproduced or translated without written permission. Contact the ACP for reprint permission.

Postmaster: Send address changes to the ACP Central Office at 211 East Chicago Avenue, Suite 1000, Chicago, IL 60611 or acp@prosthodontics.org.



Dr. John Agar is President of the ACP, and a Professor and Director of the Graduate Prosthodontics Program in the Department of Reconstructive Sciences at the University of Connecticut Health Center School of Dental Medicine.

► Page 20




Dr. Stephanie Drew is an attending oral and maxillofacial surgeon at Long Island Jewish Medical Center and Associate Professor at Hofstra NS/LIJ Medical Center.

► Page 14



Dr. Carl F. Driscoll is Program Chair of the 2014 Annual Session, Vice President of the American College of Prosthodontists, and Program Director for the Department of Prosthodontics at the University of Maryland.

► Page 22



Dr. Lily Garcia is Chair of the ACP Education Foundation and Associate Dean for Education at the University of Iowa College of Dentistry & Dental Clinics.

► Page 24




Dr. Howard Kerpen is Professor of Medical Education and Director of the Lorber Center for the Advancement of Medical Education at Long Island Jewish Medical Center.

► Page 8



Dr. Jacinthe M. Paquette is recognized internationally as a leader and educator in prosthodontics, esthetics, and implant dentistry. She maintains a private practice in Newport Beach, CA., and is Editor in Chief of the *ACP Messenger*.

► Page 6



Dr. Stephen A. Sachs is the founding surgeon of the New York Center for Orthognathic & Maxillofacial Surgery team. He is Clinical Professor, OMFS at SUNY at Stony Brook and Clinical Professor of Dental Medicine at Hofstra NS/LIJ School of Medicine.

► Page 14



Dr. Frank J. Tuminelli is President Elect of the ACP and Program Director at New York Hospital Queens Department of Graduate Prosthodontics.

► Pages 12 & 14

Can I Compete?



Competition is greater than ever for the prosthodontic practice. Referral patterns are changing. How can I stay competitive in this ever evolving industry?

Proven Practice Building For The Modern Prosthodontic Office

HYBRIDGE[®]
The revolutionary dental implant technology[™]

HYBRIDGE[®] is the optimal full arch implant procedure. By combining practice building and clinical protocols, prosthodontists have significantly grown full arch case volume and implant procedures.

- ✓ Nationally Branded Network
- ✓ Newest Technologies
- ✓ Strategic Alliances
- ✓ State Of The Art Laboratory

Ensure your relevance as a market leader. Elevate your practice to the next level with HYBRIDGE[®].

For more information about becoming a HYBRIDGE[®]
Certified Center please call (585) 319-5400

Visit HybridImplants.com today.

**Proven.
Predictable.
Prominent.**

A Patient-Centered Focus

Jacinthe M. Paquette,
D.D.S., F.A.C.P.
ACP Messenger Editor-in-Chief

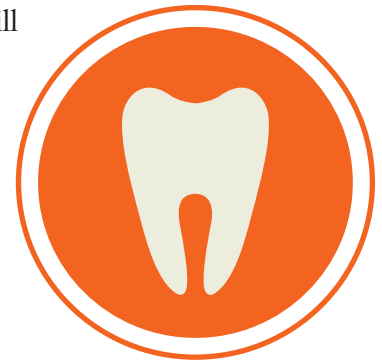The connection between oral health and systemic health is well established, and it continues to be revisited in research and literature.

For many patients, the relationship between systemic health and oral health can be easily managed. Yet for some with more serious or chronic medical conditions, oral health management can prove a challenging task requiring a sophisticated interdisciplinary treatment team and close monitoring. Prosthodontists have extensive education and training which makes them well-prepared for the management of such patients.

This issue of the *ACP Messenger* will highlight several examples of prosthodontists making significant contributions to the well-being of these special patients. One such condition is Ectodermal Dysplasia, and in this issue, Drs. Sachs, Drew, and Tuminelli will demonstrate the level of sophistication required to rehabilitate such a patient. You will see an inspiring treatment outcome achieved by an astute interdisciplinary treatment team utilizing today's state of the art therapies of osteogenic distraction and dental implant therapy.

The "For the Patient" section will review patient-friendly tips on oral hygiene along with the symptoms and solutions in treating patients with Sjogren's Syndrome. No matter how simple or complex the patient's needs, a comprehensive evaluation provides for a patient-specific treatment approach.

Dr. Howard Kerpen will illuminate some key points on bone health. More significantly, he will share insights on osteoporosis, osteonecrosis, and the state of bisphosphonates.



Tooth grinding or bruxism is a common disorder that can have deleterious effects on natural or restored dentition and the temporomandibular joints. Dr. Frank Tuminelli will address the interrelationship of bruxism and its effects. His article provides points for discussion with patients on this difficult to manage yet often overlooked condition.

Certainly, all patients requiring dental care can benefit from the added education and training that prosthodontists receive. Patients who present with a myriad of medical conditions require special cognition of the problem, reflection on possible solutions, and compassion. This expertise can especially prove to be a valuable asset in managing the complex demands of patients presenting with varied, nuanced, and complex medical conditions. ■

Neurologist Internist

Rheumatologist

Prosthodontist

Cardiologist

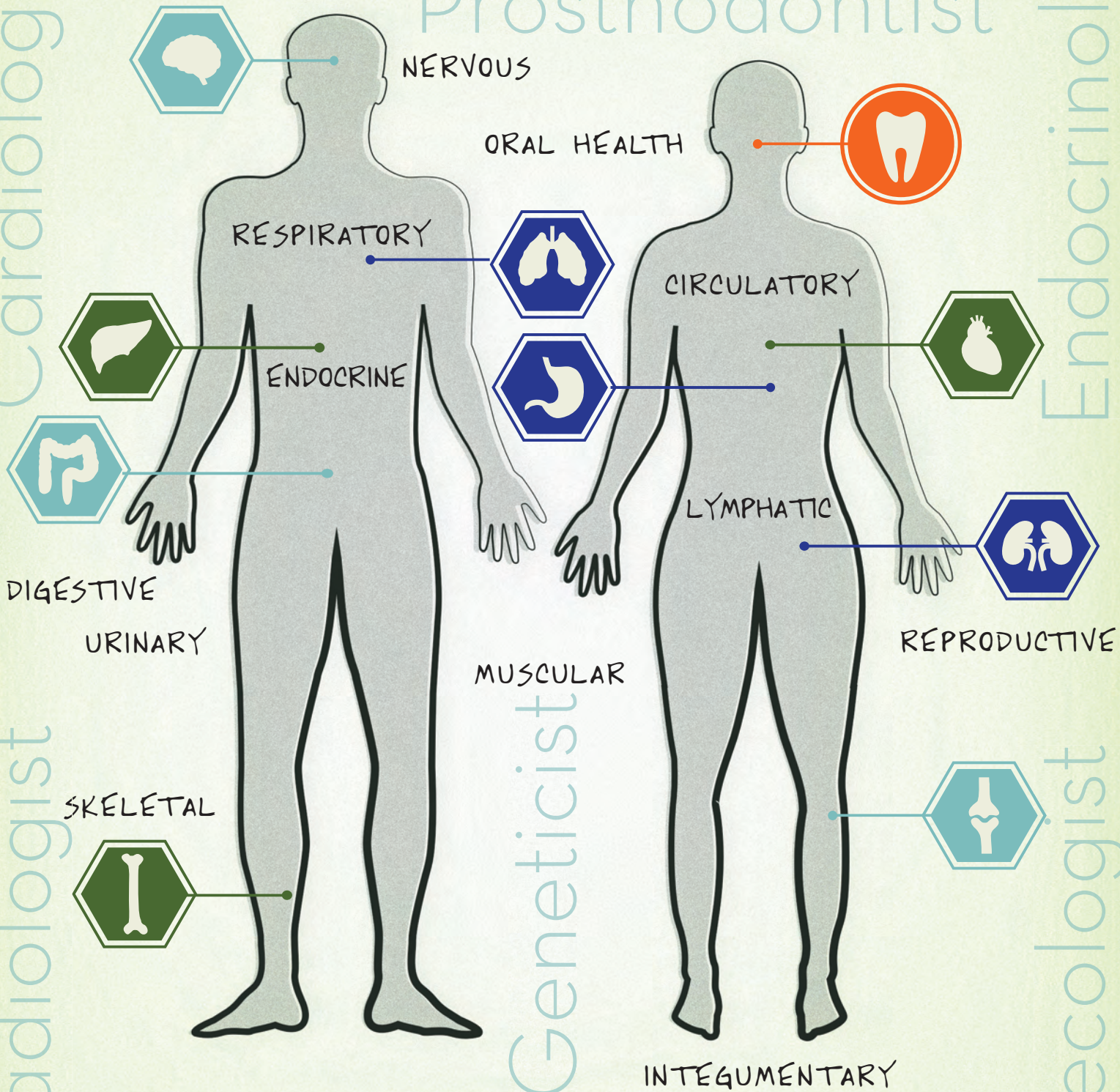
Endocrinologist

Radiologist

Geneticist

Gynecologist

Orthopedics Oncologist

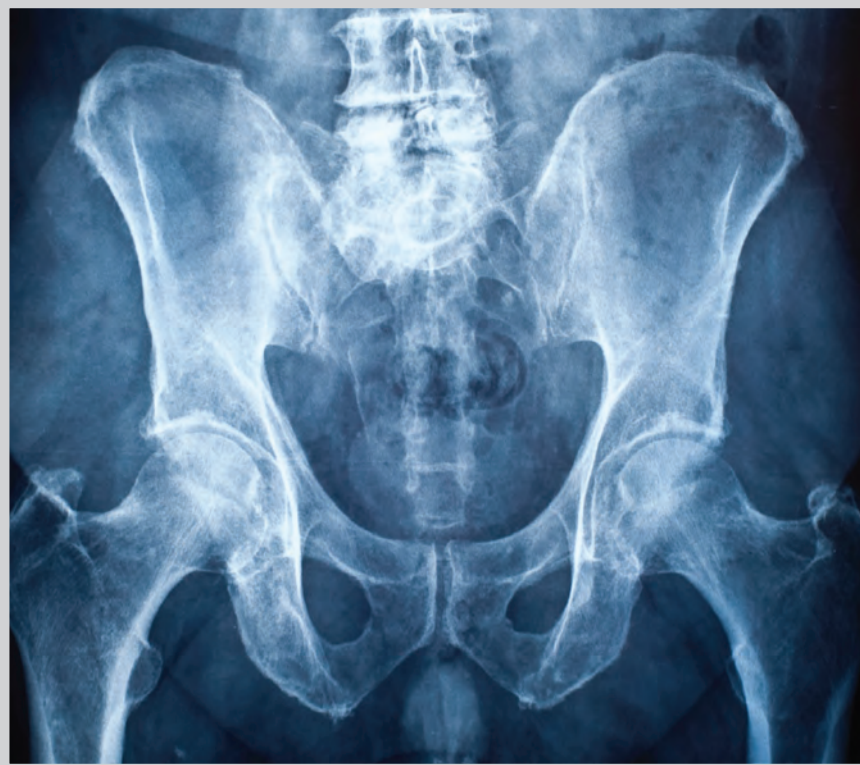

Immunologist

Treatments for Healthy Bones

Howard Kerpen,
M.D., F.A.C.P.

What's the link between treatments for healthy bones and a healthy jaw?
A close doctor/prosthodontist relationship can be key to a successful outcome.



Mrs. B., a 75-year-old woman, recently saw her internist, who noted that her blood pressure was 160 over 80. The internist started her on appropriate antihypertensive medication, in accordance with the report from the panel members of the Joint National Council Committee (JNC 8). Approximately 2 weeks after starting this medication, Mrs. B. got up at night to urinate, became dizzy, fell, and fractured her hip.

The CDC states that in 2010, there were 258,000 hospital admissions for hip fractures in those 65 years of age and older. More than 95% of these were caused by falls. They estimate that this will increase to 289,000 by 2030. In 2010, fractures were estimated to cost \$12 billion.

Historically, after a fracture, patients have been hospitalized for about one week, followed by rehab, and often a stay in a nursing home. Approximately 1/3 of the patients who lived independently prior to a fracture remain in a nursing home for over 1 year.

The mortality rate associated with hip fractures at one year has been estimated at 12-39%. Further, none of these statistics reflect the concomitant effects on the patient's family.

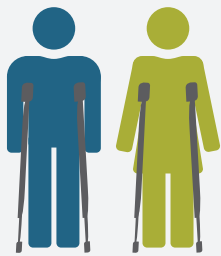
Mrs. B. is an example of a patient that an internist typically sees. The narrative that follows her case underscores the potential impact on the individual and

on our national healthcare system. She typifies why dental professionals treat so many patients on bisphosphonates and its concomitant sequelae, osteonecrosis. In fact, Wallace et.al, in the November 2013 issue of the *Journal of the American Geriatric Society*, points out that we continue to undertreat osteoporotic fractures.

Mrs. B. was on calcium, vitamin D, and exercised regularly. Most meta-analyses, including a recent one in *Lancet* (Reade et.al. December 2013), do not show a beneficial effect of vitamin D alone on osteoporosis and fracture rate. Elemental calcium supplementation may have an adverse effect on cardiovascular disease, and although exercise probably helps prevent

Number of women 50 years of age and over with osteoporosis of the hip:

4.5 million



Percentage of Americans over 50 who will experience an **osteoporotic fracture**

13%

40%

**50%
by 2020**

Estimated percentage of all Americans over the age of 50 who will be at risk of developing osteoporosis.

Hospital admissions for hip fractures for Americans over 50



In 2010
258,000



In 2030
289,000

More than
95%
of these were
caused by falls.



33%



Percentage of patients who lived independently prior to fracture who remain in a nursing home for over a year.

fractures, it probably does this more via overall fitness as opposed to a direct effect on bone. In 2009, Brauer et al demonstrated a decrease in the post fracture mortality rate, which has been ascribed to the use of bisphosphonates. Therefore, we internists are mandated to use pharmacologic interventions.

One can look at osteoporosis as being an osteoclast mediated disease. Osteoclasts are the cells that are responsible for remodeling bone. That is, they sense where bone needs to be repaired, they cause a local breakdown in that area, and then osteoblasts are called upon to repopulate the area and cause new bone to form. Simplistically, osteoporosis occurs when there is more osteoclastic activity than osteoblastic activity (not accounting for bone strength and architecture).

Osteoclasts sense where bone needs to be remodeled. Osteocytes secrete RANKL, which stimulates osteoclasts. They also secrete Sclerostin, which antagonizes Wnt, which is a factor that stimulates osteoblast generation. Currently, we have two classes of drugs that statistically reduce fractures and act upon osteoclast function. Bisphosphonates' primary action is to attach to boney surfaces and inhibit the ability of osteoclasts to work at these surfaces. The other drug is Denosumab (Prolia), which acts by binding to RANKL and inhibiting its effect on osteoclasts. Unfortunately, Prolia seems to have a similar incidence of osteonecrosis as bisphosphonates.



According to the National Institutes of Health, exercise can help maintain or even modestly increase bone density in adulthood and, together with adequate calcium and vitamin D intake, can help minimize age-related bone loss in older people. The evidence suggests that the most beneficial physical activities for bone health include strength training or resistance training.



What is Osteonecrosis of the Jaw?

Osteonecrosis of the jaw is a severe bone disease that occurs when there is a loss of blood to the bone. The primary symptom of osteonecrosis of the jaw is exposure of the bone through the gums that doesn't heal for several weeks. This exposure may occur spontaneously or more likely following an invasive dental procedure such as extraction in patients with certain risk factors.

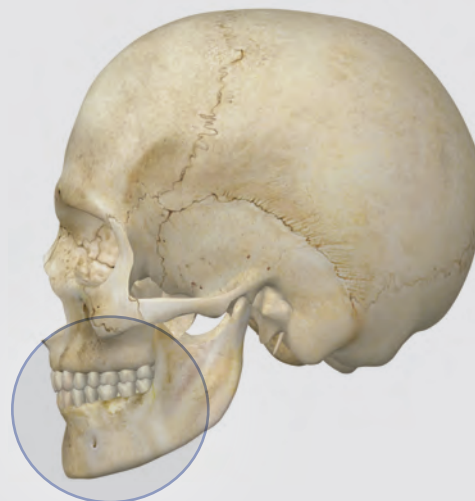Most instances of osteonecrosis occur in patients with underlying malignancies. For these patients in particular, it is recommended that there be a close doctor-dentist relationship, along with appropriate planning. An infection free environment should be attempted; procedures should be minimized, and optimally performed prior to institution of therapy. As of 2012, the American College of Rheumatology recommends a conservative approach to patients on bisphosphonates with respect to procedures in general, and for patients with periodontal disease in particular. They recommend non-surgical approaches when possible. They point out there is no evidence to support stopping bisphosphonate therapy prior to treatment, although others recommend stopping therapy 3 months prior to and post procedure.

New therapies aimed at increasing bone mass by other means are in the works. In the interim, however, those of us treating osteoporosis and low bone mass will be reducing fractures, but may unfortunately be producing some morbidity, including osteonecrosis of the jaw. ■

Patients at risk for developing osteonecrosis of the jaw include:

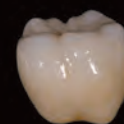- Patients receiving radiation therapy to the head and neck to treat cancer.
- Patients on long-term steroid therapy.
- Certain cancer patients with metastasis to the bone who use IV Bisphosphonates to decrease pain and the risk of bone fracture.

Although these patients have the highest risk to develop osteonecrosis of the jaw, other risk factors are advanced age, diabetes, gum disease, and smoking.

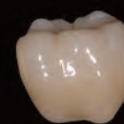

Could this be Full Zirconia?

Review our work samples at www.cuspdental.com

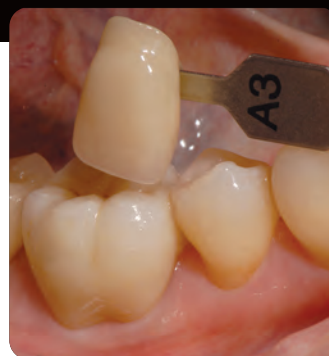

A-Light: Stained

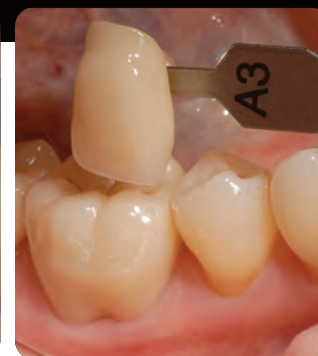

A-Dark: Polish only

Introducing new KATANA multilayered (ML) and HT Full Contour Zirconia (FCZ), now available at Cusp Dental. Obtain outstanding esthetics, durability, accuracy and high-translucency from this FCZ material. Ideal for metal-free posterior and anterior restorations, these are cost-effective and time-saving prosthetic alternatives - truly the future of CAD/CAM restoration cases.

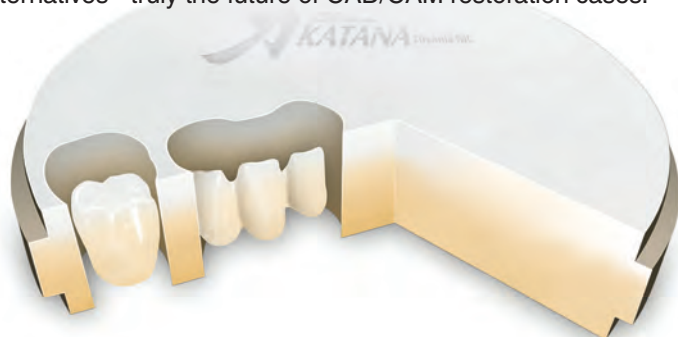


ML: A-Light



ML: A-Dark

KATANA multilayered (ML) Full Contour Zirconia



381 Pearl Street, Malden, MA 02148 toll free/ 888-267-0660 781-388-0078 info@cuspdental.com



Grinding Teeth? Talk to a Prosthodontist

Frank J. Tuminelli,
D.M.D., F.A.C.P.

Grinding, or bruxing, is not an uncommon concern for patients. Thankfully, it is treatable with conservative therapy and if diagnosed early, has minimal long term effects on the teeth and joints.

Some of the more common questions a patient may ask their prosthodontist are, “Doctor, do I grind my teeth?”, “How do I know I grind my teeth?”, and “Is it dangerous?” In other instances, a prosthodontist will tell a patient that he or she is grinding their teeth, and the patient will be surprised. Most patients do not know they grind their teeth, and it is often a significant other who makes them aware of it. It is also common for parents to report that they hear their children grinding.

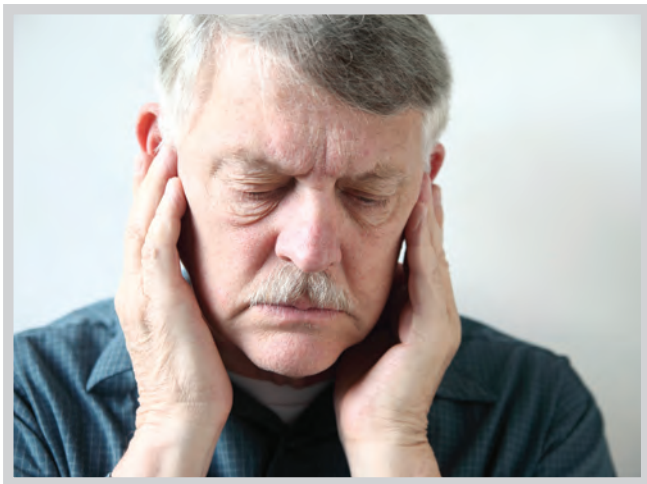Why is grinding detrimental? Excessive force on the teeth in a repetitive action will accelerate tooth wear. Wear of the permanent teeth is very rarely associated with diet, especially since humans have evolved to a more processed diet of less raw, hard, abrasive foods. Most wear and tear of the teeth is a result of the teeth grinding against each other. The reason for this is that enamel is one of the hardest substances known. It takes a dentist with a diamond or stainless steel burr rotating at high speeds to cut through it. However, teeth have a finite amount of enamel on the biting surfaces or front edges. The amount of enamel when a tooth first erupts into your mouth is the most enamel there will ever be.

The potential for greater damage occurs when the enamel is worn through to the dentin. The dentin is the yellow, orange, or brown discoloration one may see on the edges of the front teeth after years of clenching. (Most patients first notice it on the lower teeth.) This is the area that your prosthodontist may point to as evidence of grinding.



Another important sign of grinding is the canine (eye) teeth. If you look at a healthy intact canine, it has a specific anatomical profile, normally coming to a point. The canines also have a very specific role in a healthy dentition. They protect the back teeth from lateral loading in the chewing cycle by acting as a last minute “steering” mechanism enabling the teeth to all meet properly. When an individual has been bruxing (technical term for grinding), the canines wear down first, and the obliteration of the normal pointed anatomy will be visible. If this continues, the dentin is exposed, and this progresses to the other front teeth as they begin to contact during the bruxing pattern. It becomes a domino effect and the dentin becomes exposed on the incisors, as previously mentioned. This is usually after many years or decades of bruxing.

Most patients will primarily grind on one side. The rationale for this is not truly understood. It could be speculated that this is associated with whichever



side of the brain is dominant (very similar to right or left handedness).

Bruxing results in unfavorable loading of the teeth and may contribute to accelerated bone loss especially if the patient has a periodontal problem or uncontrolled inflammation. It places a great deal of stress on the temporomandibular joints (the joints that are immediately in front of the ears). This is the hinge-like apparatus that opens and closes the lower jaw. Potentially, this could result in joint wear and damage to the cushioning disc that separates the joint from the base of the skull. In its most severe state, bruxing may contribute to or be the cause of damage to the joints. This can result in joint pain and muscle discomfort around the jaws and head. Prosthodontists will refer to this as TMD (Temporomandibular Dysfunction).

There are people who habitually grind while awake. This is a habit that is treatable and may require behavior modification or therapy. Since it is done during waking hours, the destruction may be easier to control, but is significant. The good news is that, by wearing a protective device, there are ways to reduce the negative effects.

The vast majority of grinding is “nocturnal bruxing” (grinding at night), and is one of the more common dental habits. There are many reasons for grinding. It was considered to be stress-related or a result

of malocclusion (bite discrepancies) in which the brain was trying to equalize or deflect contacts that prevented teeth from coming together harmoniously. This may not be true.

There is a growing body of evidence that bruxing can be related to sleep apnea, and even the need to allow for cortisol release from neuroceptors in the central nervous system. This is similar to endorphin release, reducing the inflammatory mediators, and in itself is subconsciously “addicting”. This would be much more prevalent in the patient who grinds while awake. For the majority of the population, teeth grinding is intermittent, short in duration, not predictable in its time frame, and easily managed. Everyone has probably heard of a night guard, a device that is worn over the teeth at night. This has multiple functions: preventing further tooth wear and protecting the joints. It is a conservative approach and is easily made. In most patients, this is all the treatment that will be needed. It must be worn every night and may last from two to five years, depending on its construction and other factors. It doesn’t cure the grinding, but it controls the wear on the teeth.

For most patients, the wear on the edges of the teeth can be restored with a tooth colored material (composite). This will seal off the dentin and also restore the aesthetics of the teeth. Many times, it can even be done without an anesthetic. In some patients, if the teeth have been reduced in height, they can be restored with veneers. It would be wise to have the night guard fabricated after the teeth have been restored. Otherwise, the night guard would have to be remade, which can be costly. In some patients, though rare, grinding has caused such significant destruction to the entire dentition that a total reconstruction of all the teeth, requiring crowns, is needed.

Grinding, or bruxing, is not an uncommon concern for patients. Thankfully, it is treatable with conservative therapy and if diagnosed early, has minimal long term effects on the teeth and joints. ■

Meeting the Challenges of Ectodermal Dysplasia

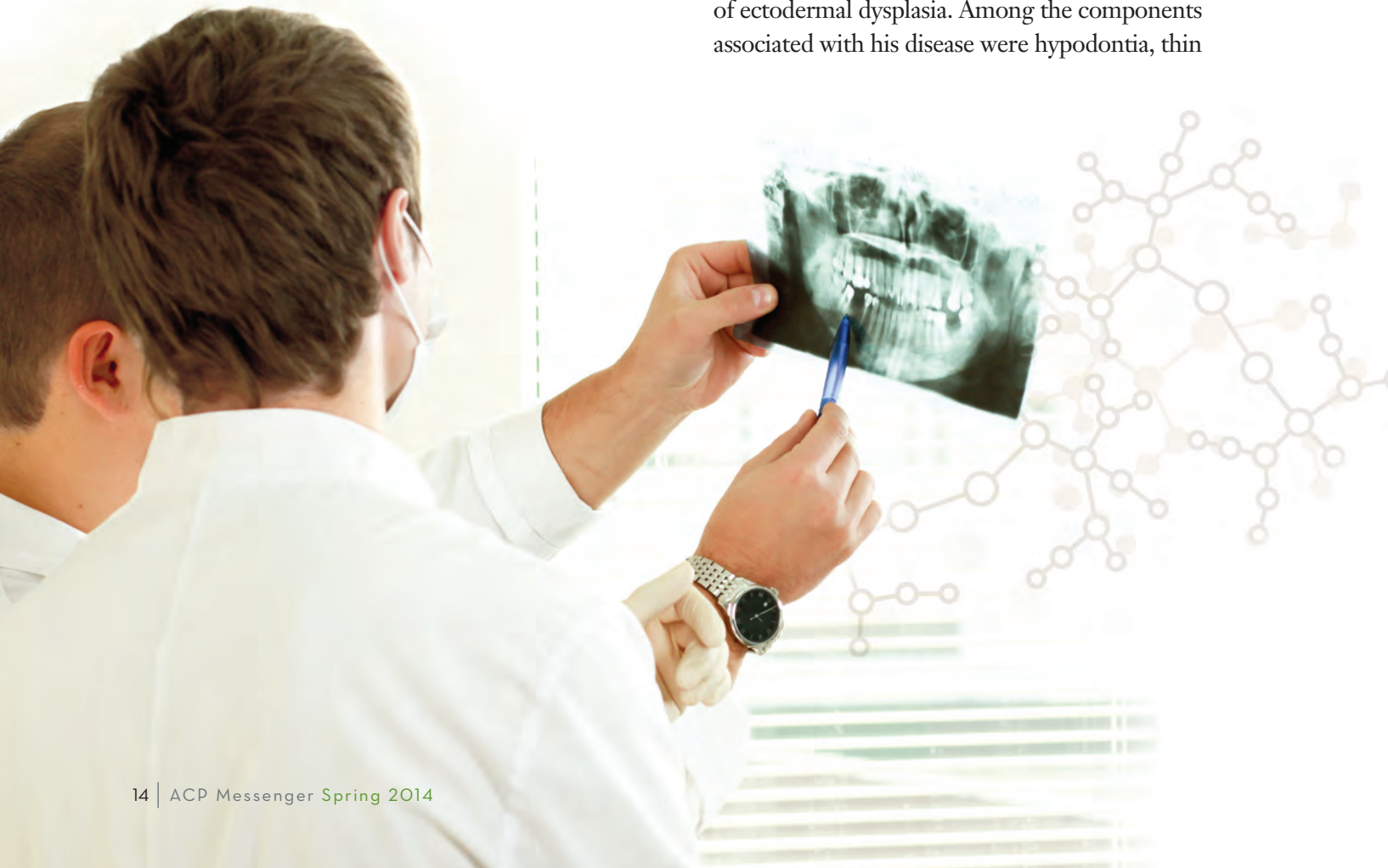
Stephen A. Sachs, D.D.S.;
Stephanie Drew, D.M.D.;
Frank J. Tuminelli, D.M.D., F.A.C.P.

Meaningful clinical advancements can develop when the dental profession allies itself with the medical profession to care for patients with complex clinical problems whose solution requires team-based, patient-centered care.

Examples include the care of oral cancer patients, patients with cleft lip and palate deformities, and dental health maintenance for patients with diabetes mellitus. One unique disease that requires significant dental rehabilitation with challenging and innovative dentistry is ectodermal dysplasia. This disease, which affects over 7,000 people worldwide, involves genetic defects of ectodermal structures including skin, hair, sweat glands, teeth, and dysmorphic craniofacial development.

Once referred to a dental care center, the patient with ectodermal dysplasia requires a comprehensive assessment and a dental restorative plan to restore normal jaw-to-jaw relationships, bone augmentation for osseointegration of endosseous implants, and prosthodontic restoration.

To illustrate these challenges and potential creative solutions, a rather complicated case will be presented. This is a 30-year-old male with a known history of ectodermal dysplasia. Among the components associated with his disease were hypodontia, thin



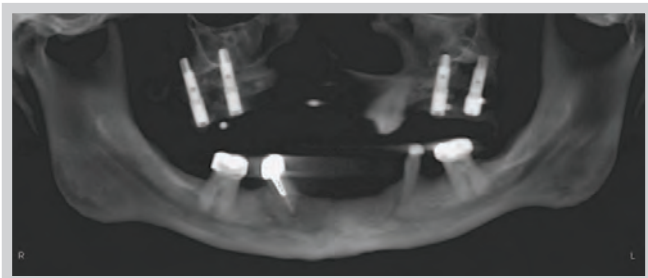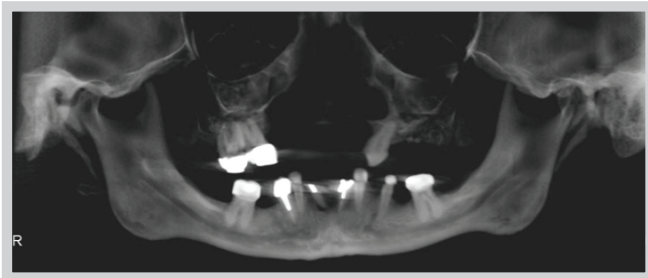


Fig. 1 (Top): A 30-year-old male with ectodermal dysplasia, hypodontia, and severe maxillary retrusion

Fig. 2 (Bottom): Bone grafted maxilla with implants and grafted mandible

absent hair, absence of sweat glands, very thin and atrophic skin, syndactyly (fused digits), and a history of several surgeries for the correction of a bilateral cleft lip and palate. The multiple missing teeth had been replaced with a failing, unstable, and unaesthetic overdenture.

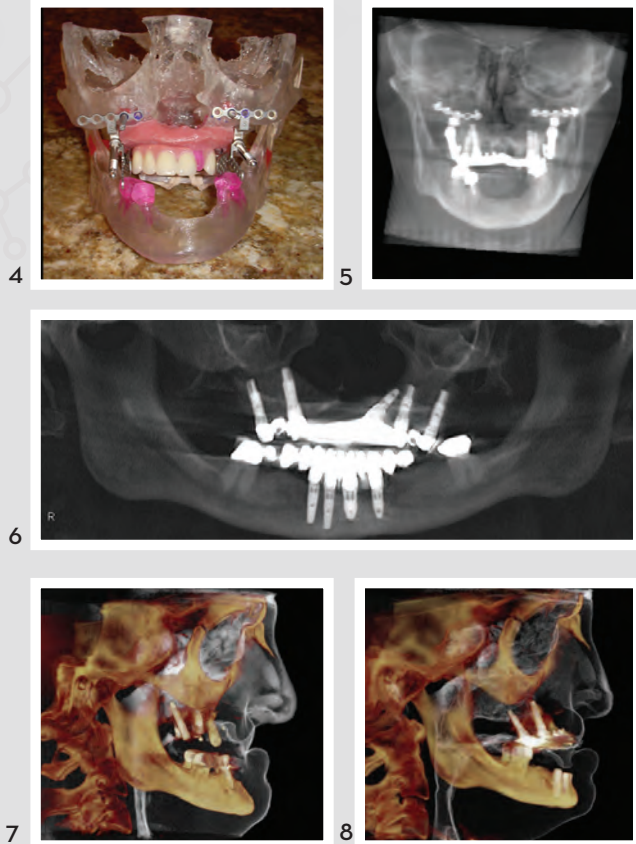
He had midface retrusion creating a significant Class III jaw-to-jaw relationship. There was a 26 mm discrepancy between the hypoplastic maxilla and mandible. Due to the magnitude of this discrepancy and the existing scar tissues secondary to the multiple surgeries of the past, a traditional craniomaxillofacial advancement was not feasible for this patient. The interdisciplinary team involved in his care determined that osteogenic distraction of the maxilla was indicated.

What is ectodermal dysplasia?

According to the National Institute of Health, ectodermal dysplasia is a group of conditions in which there is abnormal development of the skin, hair, nails, teeth, or sweat glands. It is often caused by gene defects. People with ectodermal dysplasia may not sweat or may have decreased sweating because of a lack of sweat glands; children may have difficulty controlling fevers, while adults are unable to tolerate a warm environment and need special measures to keep a normal body temperature.

The patient underwent extraction of the remaining hopeless teeth and bilateral maxillary surgery with sinus grafting and lateral augmentation to initially stabilize the maxillary base. Tibial bone was harvested for the bone augmentation procedures.

A temporary removable denture was created during this phase of the patient's care to create an esthetic and functional dentition for him during the healing phase. The grafted sites were allowed to mature for six months and osseointegration was performed with the placement of five endosseous implants in the newly grafted maxilla. At the same time, the remaining anterior mandibular teeth were removed and the extraction sites were grafted with bone morphogenic protein. Following four months of healing, four endosseous implants were placed and immediately loaded with a screw-retained prosthesis in the mandibular arch.



Figs. 4 & 5: 3D model allowed distractor placement preoperative
 Fig. 6: Final prosthesis in place
 Figs. 7 & 8: Side-by-side CBCT images: Pre-op and Post-op



Once stabilized, a temporary maxillary dentition with a metal framework was secured to the implant base and, working closely with the dental laboratory technician team, the future maxillary prosthesis in the advanced position was anticipated and constructed.

At this phase, the final efforts toward the osteogenic distraction could be initiated. A 3D Cone Beam CT (CBCT) scan was taken for both diagnostic and strategic treatment planning purposes. Through the construction of an anatomic three-dimensional model of the facial skeleton, the osteotomies for the maxilla distraction were planned and the alignment on the left and the right segments was selected. The three-dimensional model allowed adaptation of custom distractors to the maxilla. Utilization of this technology provided for better efficiency in the operating room and it allowed for selective orientation of the distracting pins.

Utilizing the mandibular dental appliance to direct the appropriate anterior/posterior dentofacial relationship (AP goal), the maxilla was treated with a modified LeFort I Osteotomy to displace the upper jaw forward and create a more favorable profile for the patient. The osteogenic distractors were incrementally turned at a rate of one half millimeter per day resulting in a mid face advancement total of 28 mm. Once the desired upper jaw to lower jaw relationship was achieved, the appliance was locked to allow final healing. Once the healing had been documented, the distractors were removed and an implant based screw-retained prosthesis was placed in the maxilla, thus creating a markedly improved dental facial relationship.

The dental rehabilitation of patients with ectodermal dysplasia requires a cohesive medical/dental team and offers an opportunity for meaningful outcomes for our patients. ■

The AAE, the AAP and the ACP invite you to attend a multidisciplinary conference to highlight contemporary evidence and best practices for **saving the natural dentition.**



Teeth for a Lifetime: Interdisciplinary Evidence for Clinical Success



Specialists in Saving Teeth



Your smile.
Our specialty.®



JOINT
SYMPOSIUM

July 19-20, 2014
Swissôtel, Chicago, Illinois

EARN UP TO **10.5** CE CREDITS

Register Today!
www.aae.org/teethforalifetime

Q&A: Oral Hygiene



Q: What is halitosis?

A: Halitosis is the medical term to describe bad breath. Although a few medical conditions may cause halitosis, the most common causes are related to the condition of your teeth and/or your dental hygiene. Broken teeth or badly decayed teeth may collect debris, and in time, bacteria forms and causes a bad taste and smell.

The first step to improving halitosis is keeping your teeth, your gums, and your tongue clean. A buildup of plaque may lead to gingivitis and gum disease, a common cause of halitosis. It is also important to brush your tongue to remove plaque and bacteria. Other causes of halitosis include certain foods, tobacco use, and dry mouth.



Q: How do I know if I'm flossing correctly?

A: Flossing is easy once you get in the habit of doing it regularly:

- Take approximately 16-18 inches of floss and wrap it around your fingers.
- Use your thumb and index finger to gently guide the floss between the teeth and through the contact area.
- When you reach the gum line, carefully move the floss up and down against each tooth reaching under the gum.
- Readjust the floss to use a clean section for every two teeth.

Initially the gums may bleed, but with regular flossing the health of the gums will improve and the bleeding will stop.

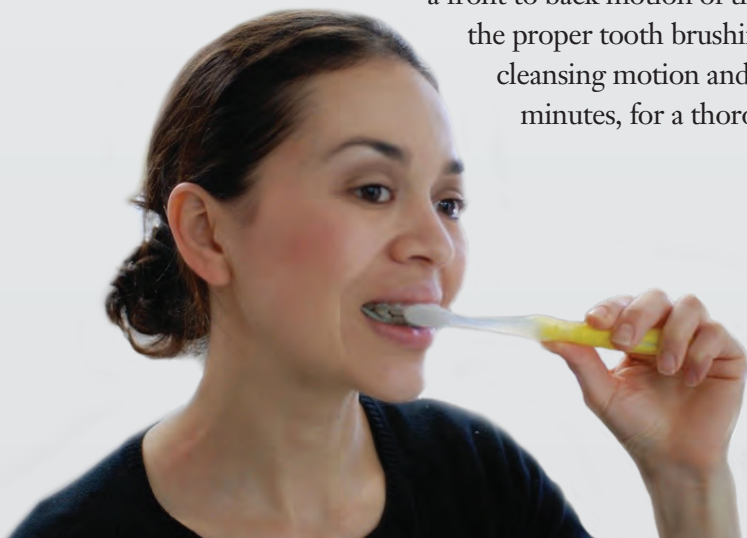

Q: How should I brush my teeth?

A: Proper tooth brushing habits are the key to maintaining a healthy, pain-free mouth.

Whether you use a manual or electric toothbrush, the same principles apply. Because it is important to clean your gums as well as your teeth, to avoid damaging the gums, you should always use a soft-bristled toothbrush.

Clean the area where the gums meet the teeth by placing the toothbrush at a 45-degree angle, touching both the gums and the teeth, and make small circles with the brush for several seconds. Then move the brush to the chewing surfaces of the back teeth and clean them with a front to back motion of the toothbrush. Electric toothbrushes may enhance the proper tooth brushing techniques by automatically providing the proper cleansing motion and encouraging a specific time interval, usually two minutes, for a thorough cleaning.



Understanding Sjogren's Syndrome

Sjogren's Syndrome is a chronic inflammatory disease that can have a significant impact on a patient's oral health. It is an auto-immune disease whose cause is still unknown and occurs approximately nine times more in women than in men. It is characterized by lymphocytic infiltration of the endocrine glands, particularly the salivary and lacrimal glands that produce saliva and tears, and it causes dysfunction and structural damage of these glands leading to xerophthalmia (dry eyes) and xerostomia (dry mouth). It is important that a patient suspected to have Sjogren's Syndrome is evaluated by a multidisciplinary team of health care providers including ophthalmologists, otolaryngologists, and prosthodontists.

Oral symptoms may include burning oral mucosa, early tooth loss, increased tooth wear, poor tolerance with removable dentures, and a high caries rate.

Preventive dental treatment is extremely important as the lack of saliva creates an ideal environment for the proliferation of bacteria that cause dental caries (cavities).



A personalized preventive regimen may include at-home topical fluoride application to strengthen tooth enamel, saliva replacements, and frequent teeth cleanings by a dental hygienist. Existing cavities must be treated to prevent the high risk of spreading into the pulp of the teeth, leading to more extensive treatments or even tooth loss.

Patients with Sjogren's Syndrome need to be properly guided and closely monitored. It affects people not only physically but also emotionally and socially. Prosthodontists are trained to diagnose this disease and apply a comprehensive therapy in order to provide the best quality of life.

WHEN FACED WITH A MALPRACTICE CLAIM, WHO DO YOU WANT IN YOUR CORNER?



One company has strength and experience that towers over the others.

When your career and reputation are on the line, you want the strongest dog in your corner. Many dentists don't realize how important their dental malpractice insurance is until they need it most. Medical Protective has over 100 years of proven experience, national expertise and a balanced defense that focuses on *your best interest*. And, today, more than ever, the big financial strength, integrity and powerful backing of a Warren Buffett Berkshire Hathaway Company are crucial to the quality of your dental malpractice protection.

Treloar & Heisel, Inc. | Affinity Partner
Visit www.th-online.net | Call (800) 345-6040

ACP

AMERICAN COLLEGE OF
PROSTHODONTISTS

Your smile.
Our specialty.®

Treloar
& Heisel, Inc.

Trust the dental malpractice experts.

Medical
Protective

a Berkshire Hathaway company

Strength. Defense. Solutions. Since 1899.

©2014 The Medical Protective Company®

Our Specialty's Success Depends on Volunteers

John R. Agar,
D.D.S., M.A., F.A.C.P.
ACP President

Volunteering to serve on committees, task forces, and the Board of Directors is an “above and beyond” commitment.

It is essential to have volunteers who contribute their time, energy, and talent for the ACP to accomplish its goals and objectives. Prosthodontics as a specialty would not exist without ACP members paying dues to cover costs for our efforts toward advocacy and education, but it also depends on the members who volunteer to do jobs that sustain our specialty. Volunteering to serve on committees, task forces, and the Board of Directors is an “above and beyond” commitment.

ACP committee chairs and committee members' responsibilities require different levels of commitment and some are particularly substantial. The various positions on the ACP Board of Directors involve different amounts of time but all compete with volunteers' other professional and personal obligations. Serving as an officer requires considerable commitment. I am able to serve as the ACP President because of the support of my Department Head and Assistant Program Director. Those in private practice sacrifice considerable patient care time to serve on the Board of Directors or as an officer.

Some ACP members have volunteered and yet have not gotten the opportunity to serve on committees.



ACP leaders try to manage all the offers to serve but reasons for not being used may be that a particular position isn't available because it is filled with other volunteers at the time or an individual's availability is lost in the logistics of populating committees. Please continue to volunteer until a position opens. Populating committees with interested, dedicated volunteers is so important and truly appreciated. This year the President, Executive Committee, and Directors included the chairs in the process of populating their committees and task forces. Committee and task force chairs contacted each of their members to ensure they were interested

in serving. Some members wanted to serve. Some members requested relief from being on the committee for various reasons and some members did not respond. Positions were filled with individuals who confirmed their commitment to serve.

Dr. Julie Holloway presented a proposal during the February Board of Directors meeting to improve the timeline by which committees are formed. The exact timeline designated for the population and tasking of committees is on schedule to be completed during the June BOD meeting.

Future issues of the *ACP Messenger* will highlight committees and their activities. This will be done to acknowledge the good work of our committees and to

ACP committee chairs and committee members' responsibilities require different levels of commitment and some are particularly substantial.

educate members about ACP Committee volunteers' accomplishments. This will also inform you about potential volunteer activities in which you may be interested. Please watch for further information about how to be involved as an ACP Volunteer in future issues of the *Messenger* and in the ACP *Wednesday Wake-up Call*.

My thanks to all of you for your support! ■



Specialists
rely on
Specialists.®

ACP | AMERICAN COLLEGE OF
PROSTHODONTISTS
Your smile. Our specialty.®

Treloar
& Heisel, Inc.
An Affinity Partner

Professional Association Insurance Administrators • 1-800-345-6040 • th-online.net

“Get Real” in New Orleans

Carl F. Driscoll,
D.M.D., F.A.C.P.
Annual Session Program Chair

What are the costs and benefits of moving toward CAD/CAM and advanced digital technology in your practice? How do you lead the collaboration between a team of specialists? What legal considerations do you need to anticipate in patient management?



You’ve been to meetings where the speakers show off the beautiful work they’ve done, the cases where everything went according to plan and nobody broke a sweat.


This isn’t one of those meetings.

At the 44th Annual Session of the American College of Prosthodontists, it’s time to “Get Real.” This is a program about problems in real life prosthodontics, the challenging cases we see on a daily basis – the complications, failures, and solutions that define our specialty.



What are the costs and benefits of moving toward CAD/CAM and advanced digital technology in your practice? How do you lead the collaboration between a team of specialists? What legal considerations do you need to anticipate in patient management?

On Thursday morning, we’ll hear from our co-specialists. An oral surgeon, a pharmacologist, and other dental specialists will bring their perspectives to the table. As leaders in comprehensive, patient-centered care, we need to know what the other specialties are doing, from the dental implications of patient medications to digital planning and cross-specialty collaboration.



Thursday afternoon is about diagnostic considerations and legal consequences. Speakers with extensive experience in law and prosthodontics will share their hard-earned stories. Liability may not be covered in most residencies, but it’s an everyday concern for practitioners. It’s better to prevent than react.

ACP2014

PROSTHODONTICS

44TH ANNUAL SESSION • NOV. 5-8 • NEW ORLEANS

On Friday, it's a full day of complications, failures, and solutions. An exceptional group of researchers, educators, and practitioners will examine causes for esthetic implant complications and show you how to evaluate the true cost of big-ticket technology purchases. Accompanying them will be presentations on ceramic restorations and CAD/CAM, peri-implant hard and soft tissues, and much more.

Throughout the week, there will be opportunities to meet with old friends, network with colleagues, and get up to date on the very latest from the specialty. The Welcome Reception on Wednesday evening is sure to be one of the highlights of the year, while an incredible program at the cutting edge of digital and laboratory solutions awaits on Saturday.

The Hyatt Regency in New Orleans is a spectacular hotel, one of the showcase Hyatt properties. Fully renovated after Hurricane Katrina, the Hyatt Regency is a state-of-the-art venue for state-of-the-art learning. The rooms are centrally located, with no long walks between sessions. And the sights of New Orleans, from world-class dining and live jazz to the historic French Quarter, are a few blocks away.

As you know, there's more to real life prosthodontics than the pretty stuff. But if you don't have problems, you won't have solutions – and the ACP's 44th Annual Session is about the solutions. ■

We'll see you in New Orleans!



Images courtesy of the New Orleans Convention and Visitors Bureau



Doing More with More

Lily T. Garcia,
D.D.S., M.S., F.A.C.P.
Chair, ACP Education Foundation

Thank you for supporting the ACPEF.
Plain and simple...we can do more with more.

When you support the ACPEF, we – the volunteer leaders – work on behalf of the specialty and the discipline of prosthodontics to ensure our collective future. Together, we have outstanding collective strength and influence in the professional community. Our colleagues, as leaders in corporate entities, perceive this – since many of them work directly with each of you. It is these engaged professional relationships that we highlight to build on our successes.

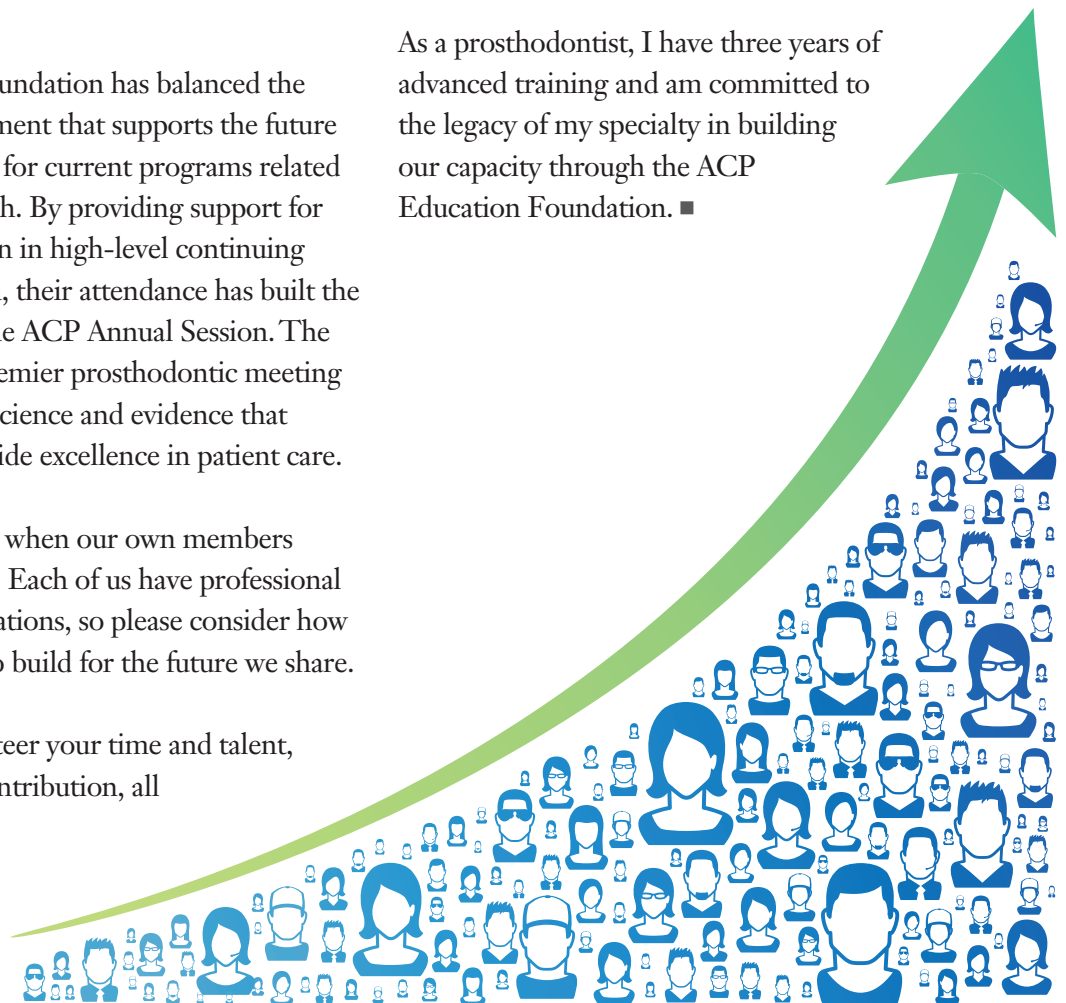
The ACP Education Foundation has balanced the need to build an endowment that supports the future while providing support for current programs related to education and research. By providing support for our resident participation in high-level continuing prosthodontic education, their attendance has built the energy experienced at the ACP Annual Session. The Annual Session is the premier prosthodontic meeting reflecting foundational science and evidence that enables so many to provide excellence in patient care.


Our message is stronger when our own members support the Foundation. Each of us have professional as well as personal obligations, so please consider how you can help continue to build for the future we share.

Whether you can volunteer your time and talent, or provide a financial contribution, all are welcomed.

We have had great support from many of you and for that I say THANK YOU! For others who are questioning whether or not they can contribute, please consider that you invested in your professional development when you completed an advanced education program in prosthodontics. You represent the best of what defines professional oral health care for so many patients. Please continue the legacy in support of our specialty.

As a prosthodontist, I have three years of advanced training and am committed to the legacy of my specialty in building our capacity through the ACP Education Foundation. ■





NATIONAL
PROSTHODONTICS
AWARENESS WEEK

April 6-12, 2014

Together, we made an impact!

From April 6-12, ACP members across the world took part in creative, inspiring events and activities to raise public awareness of the prosthodontic specialty. That's a great reason to celebrate!



GoToAPro.org/NPAW

ACP
AMERICAN COLLEGE OF
PROSTHODONTISTS

Your smile.
Our specialty.®



NOV. 5-8, 2014 • HYATT REGENCY • NEW ORLEANS

ACP2014

PROSTHODONTICS

44TH ANNUAL SESSION • NOV. 5-8 • NEW ORLEANS

Registration opens in May
acp44.com

WEDNESDAY

Advances in Maxillofacial Prosthetics

THURSDAY

Complications and Treatment from
Our Co-Specialists

Diagnostic Considerations and the
Legal Consequences That Follow

FRIDAY

Complications, Failures, and Solutions
in Prosthodontics

SATURDAY

Pre-Prosthetic Surgery, Practice
Management, and Laboratory





In the Latest *Journal of Prosthodontics*

Patients experiencing the permanent condition of ‘tooth loss’ expect that their replacements will provide adequate performance for an extended period of time. They may be less aware that tooth loss is similar to other chronic conditions in medicine and requires long-term management. Dr. Matilda Dhima (pictured) and colleagues retrospectively analyzed 255 patients who had received dental implants at the Mayo Clinic and finished their treatment there, some beginning their treatment as early as 1981.

The data presented show that anticipated and unanticipated prosthetic events occurred throughout the lifespan of the hybrid prosthesis. Prosthetic events significantly surpassed (4 times more) biologic events and occurred significantly later in the follow-up.

This is the first article in the prosthodontic literature to provide patient-based evidence on the need to manage edentulism as a “chronic disease,” and the first and only article to provide such long-term patient-based evidence, with up to a 29-year follow-up.

According to Dr. Alan Carr, a Professor of Dentistry at the Mayo Clinic College of Medicine, one of the project’s co-authors, “Like diabetes or high blood pressure, tooth loss is a long-term chronic condition. Dental implants can be successfully used to manage the condition, yet like other chronic conditions, will need consistent follow-up and maintenance care.”

Dhima M, Paulusova V, Lohse C, Salinas TJ, Carr AB Practice-Based Evidence from 29-Year Outcome Analysis of Management of the Edentulous Jaw Using Osseointegrated Dental Implants. *J Prosthodont* doi: 10.1111/jopr.12084



Staffileno Family Head and Neck Cancer Dental Symposium

Lee M. Jameson, D.D.S., M.S., F.A.C.P.

Exceeding all expectations, the first annual Staffileno Family Head and Neck Dental Cancer Symposium was held in Chicago on January 17, 2014 with over 140 participants. The symposium was presented by the Lurie Cancer Center of Northwestern Memorial Hospital, the American College of Prosthodontists, and the American Academy of Maxillofacial Prosthetics.

Dr. Mark Hutten of the ACP Board of Directors served as the host and presented an outstanding lecture on “Goals and Objectives of the Pre-Radiation Treatment Dental Evaluation.” ACP and AAMP Fellow Dr. David Reisberg’s presentation “Prosthetic Reconstruction and Long-Term Maintenance” emphasized the high degree of collaboration between medicine and prosthodontics and the significance of the patient as part of the team approach to cancer management. Oral pathologist Dr. Mark Lingen

reviewed oral cancer screening devices/tests, incidence of HPV infections, and methods of intervention/prevention.

Three Northwestern Memorial Hospital physicians represented the medical portion of the head and neck cancer treatment team. Radiation oncologist Dr. Urjeet Patel discussed the current surgical management for patients with head and neck cancer including trans oral robotic surgery (TORS), oromandibular reconstruction, and virtual surgical planning. Dr. Samir Sejjal covered how to manage the side effects of radiation therapy with emphasis on osteoradionecrosis, xerostomia, dysphagia, and mucositis. Other topics Dr. Sejjal discussed included 3D-CRT, intensity modulated radiation therapy (IMRT), dose thresholds, and image guided radiation therapy. Dr. Ryan Gentzler from the Department of Hematology/Oncology provided a thorough review of concomitant chemoradiotherapy, induction chemotherapy, sequential therapy, and HPV-associated oropharynx cancer.

Welcome New Members

December 2013 –February 2014

New Member

Dr. Joseph T. Luke

Reinstated Members

Dr. Vladimir R. Jovic
 Dr. Kavitha P. Das
 Dr. Diana Lee
 Dr. Matthew Milner
 Dr. Kirk E. Houston
 Dr. Mahmoud M. Serag
 Dr. Stephan S. Porter
 Dr. Federico Diez
 Dr. Namrata Nayyar
 Dr. Glenn E. Minsley
 Dr. Lisa O. Stoner
 Dr. Manlio Zuniga

Reinstated Fellows

Dr. Scott D. Wright
 Dr. Tarek S. AbdelHalim

Reinstated

International Fellow

Dr. Kwansiri Plengsombut

New Academic Alliance Members

Dr. Gregory Essick
 Dr. Gustavo Mendonca
 Dr. Thomas Ziemiecki

New Student Members

Dr. Ahmed M.R. Affify
 Dr. Alessandro Milani
 Dr. Leila Ahmadian
 Dr. Nalah Abdulrahman AlGhanaim
 Dr. Manar Mohammed Alzahrani
 Dr. Aditi A. Kulkarni

New Predoctoral Student Alliance Members

Ms. Reema Kalpesh Patel
 Mr. Emeka A. Ezeokeke
 Mr. Devon L. Gilkes

Mr. Farzad R. Moghaddam
 Mr. Matthew W. Goldstein
 Ms. Elizabeth L. Sand
 Ms. Melissa P. Mazlin
 Mr. Michael A. Siy
 Ms. Eve E. Lofthus
 Ms. Mandy Alamwala
 Ms. Bethany D. Brooks
 Ms. Cristin B. Haase
 Ms. Heather A. Blackmond
 Mr. Daniel Margolis
 Mr. Eric C. Hu
 Mr. McKinley D. Soult
 Mr. Albert C. Park
 Mr. Christopher Lee
 Mr. Stephen P. Barba
 Ms. Lauren H. Katz
 Mr. Geoffrey R. Morris
 Mr. Brent S. Ford
 Ms. Agnieszka M. Iwaszczyszyn
 Ms. Alena Bukhar
 Mr. Alex C. Moore
 Mr. Alexander G. Brodeur
 Mr. Alexander M. Munaretto
 Ms. Amatul A. Salma
 Ms. Amena Tamkenath
 Mr. Matthew S. Anderson
 Ms. Ankita Kaur
 Ms. Annamarion Kolencherry
 Mr. Anthony M. Lotesto
 Ms. Asra Albayatti
 Mr. Barima S. Adjei
 Mr. Chad M. Goeke
 Mr. Chander S. Gupta
 Ms. Courtney M. Botica
 Mr. Craig C. Brown
 Mr. Danté J. Brown
 Mr. David O. Reisinger

Ms. Deborah J. Yim
 Ms. Dorina Nastase
 Mr. Eric M. Moy
 Ms. Eva Bici
 Ms. Farah Talib
 Ms. Fatima N. Siraj
 Ms. Fatima N. Saeed
 Ms. Haein Kil
 Ms. Irena T. Todorova
 Ms. Jeri K. McCombs
 Ms. Jihan Doss
 Mr. John C. Luczak
 Mr. Justin A. Bortz
 Ms. Khushbu Barot
 Mr. Kwunho K. Jung
 Ms. Luma A. Odeh
 Ms. Madhavi Gadde
 Ms. Mariam Mesa Garcia
 Mr. Matthew M. Pearce
 Mr. Max Woolf
 Ms. Mi R. Jang
 Ms. Mina Hwang
 Ms. Ming Ding
 Ms. Mollie K. Rojas
 Ms. Morae K. Kang
 Mr. Mustafa G. Alsafi
 Ms. Nancy Nguyen
 Ms. Natasha Kanchwala
 Ms. Navjit Kaur
 Ms. Navjot K. Randhawa
 Mr. Nirmaldeep Singh Brar
 Ms. Nisha Garg
 Mr. Norris P. Navoa
 Ms. Olga Kats
 Mr. Omar Aldoori
 Mr. Onkar S. Dadijala
 Ms. Parisa Jaberabo Ansari
 Mr. Pierce J. Brown
 Mr. Pratik Patel
 Ms. Prutha B. Parikh
 Ms. Punita R. Shukla
 Mr. Rachit K. Shah

Mr. Ramanpreet S. Nanra
 Ms. Randa Nakib
 Mr. Ritesh Diwan
 Ms. Sabrina Mangat
 Ms. Samar B. Syed
 Ms. Sapana A. Parikh
 Ms. Shohreh Raof
 Mr. Shouvik Ponnusamy
 Ms. Shruti Tandon
 Ms. Stacey M. Chibe
 Mr. Stephen R. Griffith
 Ms. Sundeep Kaur
 Mr. Vincas V. Sidrys
 Mr. Vivek Patel
 Mr. Syed Rehman
 Mr. Vu Quach
 Mr. Taras Martyniuk
 Mr. Wasim Hanna
 Mr. Mark Anthony White
 Mr. Tarnit S. Kapoor
 Mr. William M. Burns
 Mr. Yaser Shaheen
 Mr. Zachary Tilden
 Mr. Thomas J. Angerame
 Mr. Tudor C. Chertes
 Mr. Jason A. Dale
 Ms. Milagritos Rios
 Mr. Dipak Suri
 Ms. Nelcy J. Sanchez
 Mr. Nathan A. Kupperman

Omission

In the Winter 2014 issue of the *ACP Messenger*, Dr. Talal Alnassar was inadvertently omitted from the list of new fellows and diplomates of the American Board of Prosthodontics.

We regret the omission and congratulate Dr. Alnassar on his achievement.

Employment Opportunities

California (Concord) – Looking for an Associate Prosthodontist for a busy multi-specialty practice and Implant Center in Concord, CA. Position will be part-time and room to grow to make it full-time. Please email me your resume at khazaee@yahoo.com

Indiana (Indiana University) – Indiana University School of Dentistry invites applications for the position of Chair of the newly established Department of Prosthodontics. The administrative expectations of the Chair include leadership of the departmental faculty, staff, and students, programmatic oversight in both pre-doctoral and post-doctoral education, strategic recruitment of outstanding faculty, fiscal responsibilities, and planning. The successful candidate should have academic leadership experience, a national reputation in the discipline of prosthodontics, documented success in leading strategic initiatives, and demonstrate a strong record of scholarship and research in Prosthodontics.

Qualified applicants must be eligible for tenure at the rank of full professor at Indiana University Purdue University Indianapolis. Minimum credentials from a CODA accredited program include both a DDS or DMD and completion of a post-doctoral prosthodontic program, Diplomate status by the American Board of Prosthodontics, and eligibility for licensure in the State of Indiana. Rank and salary will be commensurate with the candidate's qualifications, experience, and credentials.

Please send a complete electronic application with the following documents:

- Signed letter of intent
- Complete curriculum vitae
- Names of three professional references with contact information.
- For tenure, three additional professional references of persons who will be able to provide an objective assessment of the candidate's academic contributions and scholarship will be required.

- Documents should be sent to dsxecaf@iupui.edu with the subject line reference posting #IN-DENT 13014.

Review of applicants will begin immediately with an anticipated appointment start date of July 1, 2014. Indiana University is an equal employment opportunity/equal access/affirmative action employer and a provider of ADA services.

Indiana University School of Dentistry is located on the IUPUI campus near the heart of downtown Indianapolis. The School of Dentistry is the only dental school in the Hoosier state and educates 80% of the dentists practicing in Indiana and offers an extraordinary learning environment in which teaching, research, and community service are uniquely combined to prepare tomorrow's dental professionals. www.iusd.iupui.edu

Iowa (University of Iowa) – The University of Iowa's College of Dentistry is searching for full-time clinical or tenure-track faculty in the Department of Prosthodontics. Position available March 2014; screening begins immediately. Must have: DDS/DMD or equivalent; and by time of appointment, Master's Degree or Certificate in Prosthodontics from an ADA-accredited dental school. Tenure track applicants must also have: research training/experience; and demonstrated scholarly/professional growth commensurate with time following advanced education completion. Desirable: clinical experience via private, military, or institutional practice; board certification; and teaching experience. Academic rank/track/salary commensurate with qualifications/experience. Learn more and/or apply at Jobs@UIowa: <http://jobs.uiowa.edu/content/faculty/>, reference Req #63801. *EEO/AA employer; women/minorities encouraged to apply.*

New York/New Jersey – Full Time Prosthodontist for busy Implant Center that performs multiple full arch implant cases including All on 4. The candidate will be expected to work in two to three

locations in New York City and New Jersey. The compensation package for the right candidate will be competitive. Contact prosthodontistnewyorkjob@gmail.com.

Oklahoma (Tulsa) – Practice Opportunity in Oklahoma: Outstanding opportunity for progressive Prosthodontist to join existing implant based practice in Oklahoma. This opportunity is a private practice based and not affiliated with a corporate DSO. This is a practice develop opportunity with unlimited potential. Oklahoma is an excellent place to live and raise a family. Low cost of living, stable economy, excellent public and private schools, and a plethora of beautiful lakes are just a few of the advantages of living in Oklahoma. For additional information please send resume and contact information to tttranch22@gmail.com



West Virginia (West Virginia School of Dentistry) – West Virginia University School of Dentistry is seeking applications for two full time clinical or tenure track faculty positions at the Assistant/Associate Professor level in the Department of Restorative Dentistry. Applicants should be experienced Prosthodontists and/or Restorative Dentists. Responsibilities will include pre- and post-doctoral didactic and clinical teaching in prosthodontics, restorative dentistry, scholarly activity, and faculty practice.

Candidates must be eligible for a West Virginia dental license; information regarding licensure in WV can be obtained at www.wvdentalboard.org. The Department of Restorative Dentistry currently includes the disciplines of operative dentistry, prosthodontics (fixed, removable, and implant prosthodontics), and dental materials. A successful candidate will have a history of documented competence in teaching, administration, and research and will demonstrate excellent interpersonal and communication skills. Individuals with experience in

curriculum development and revision are encouraged to apply.

West Virginia University School of Dentistry is located in the historic community of Morgantown, West Virginia. A thriving economy, dynamic university community, nationally ranked school system, four season climate, and breathtaking scenery make Morgantown a very attractive place to relocate professionally and personally. Over the past four years, Morgantown has ranked nationally among the very best small cities in the US for quality of life. Located only 75 miles south of Pittsburgh, Morgantown is easily accessible to major metropolitan areas in the East and Midwest.

Review of applications will begin immediately and will continue until the position is filled by a qualified candidate. Salary will be commensurate with qualifications and experience. Interested individuals should submit a letter of interest, current curriculum vitae, and names, addresses, and phone numbers of three references to Dr. Matthew Bryington, Assistant Director of Graduate Prosthodontics, Department of Restorative Dentistry, West Virginia University School of Dentistry, P.O. Box 9495, Morgantown, WV 26506-9495. West Virginia University is an Affirmative Action/Equal Opportunity Employer. WVU Health Sciences Center is a smoke free campus. West Virginia University is the recipient of an NSF ADVANCE award for gender equity. For more information on the School of Dentistry and Health Sciences Center see www.hsc.wvu.edu/sod/ or www.hsc.wvu.edu/.

Practices for Sale

Arizona – Seeking a change of location for lifestyle or professional opportunity? Would you like to live in an affluent, desirable Arizona location? Consider this spacious and beautiful, fee-for-service prosthodontic practice being offered at a very reasonable price. Established 30 years with an excellent reputation in the community, this practice provides a profitable mix of removable, fixed, and implant dentistry. Collections exceeded \$1,330,000 in 2013. Call (888) 789-1085, visit www.practicetransitions.com.

California (San Francisco) – High quality and state of the art prosthodontic practice for sale in downtown San Francisco. For more information, please send a cover letter and current CV to molinelli@aol.com or call Stephen Molinelli of Northern California Practice Sales at 650-347-5346.

Hawaii (Maui) – Comprehensive Maui restorative practice. All phases of prosthodontics, perio, implant placement. In practice over 30 years. Dr. desires to complete existing cases in the transfer of the practice. Excellent opportunity to grow the practice on the best island in the world. Email: mauiddsmsd@yahoo.com or (808) 205-2432.

Massachusetts (Cape Cod) – Adult Restorative/Prosthodontic-Implant practice. Located on rapidly growing Cape Cod; we are a fee for service

practice, with general dentist, prosthodontics and periodontist working weekly. Four operatories, 2 hygienists. The office is conveniently situated close to airport, downtown, malls, transportation center, and Nantucket ferries. Excellent opportunity for growth in an expending vibrant retirement community. Please contact Arthur Gordan of Northeast Dental Consultants for details @ 978-774-2400 or Arthur@thedentalbroker.com.

Washington, D.C. Area (Alexandria, VA) – Restorative, cosmetic, fee for service practice. Panky, LVA trained. Gross 700K 3 days/week. Also Baltimore, MD one day denture center grossing 750K. In-house lab. Shopping center site. Website www.polcariassociates.com, (800) 544-1297, info@polcariassociates.com.

Washington (Seattle) – Prosthodontic practice for sale in the greater Seattle area. A rare and unique opportunity! An outstanding practice with high production and very high profitability and cash flow. Building is in a great location with plenty of parking and visibility. Building could eventually be for sale to prospective buyer. Experienced staff will stay on with the practice. Owner also would stay on 1-2 days per week for up to a year to ensure a smooth and complete transition. On site lab. Contact Buck Reasor, DMD. Cell: 503-680-4366. Fax: 888-317-7231. Email: reasorprofessional dental@gmail.com. Website: www.reasorprofessional dental.com.

Upcoming Events



July 19-20, 2014

Joint Symposium

Teeth for a Lifetime: Interdisciplinary Evidence for Clinical Success

American College of Prosthodontists
American Association of Endodontists
American Academy of Periodontology

Swissôtel, Chicago

aae.org/teethforalifetime

Sept. 12-13, 2014

Prosthodontic Review Course

American College of Prosthodontists
Chicago

GoToAPro.org

Nov. 5-8, 2014

44th Annual Session

American College of Prosthodontists
Hyatt Regency, New Orleans

acp44.com

ASTRA TECH
IMPLANT SYSTEM



Join the **EV**olution

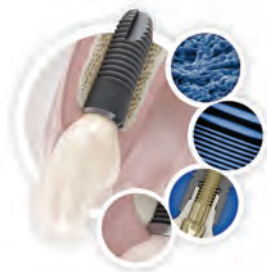

The new
ASTRA TECH Implant System™ EV
– now available

Learn more



www.jointheev.com

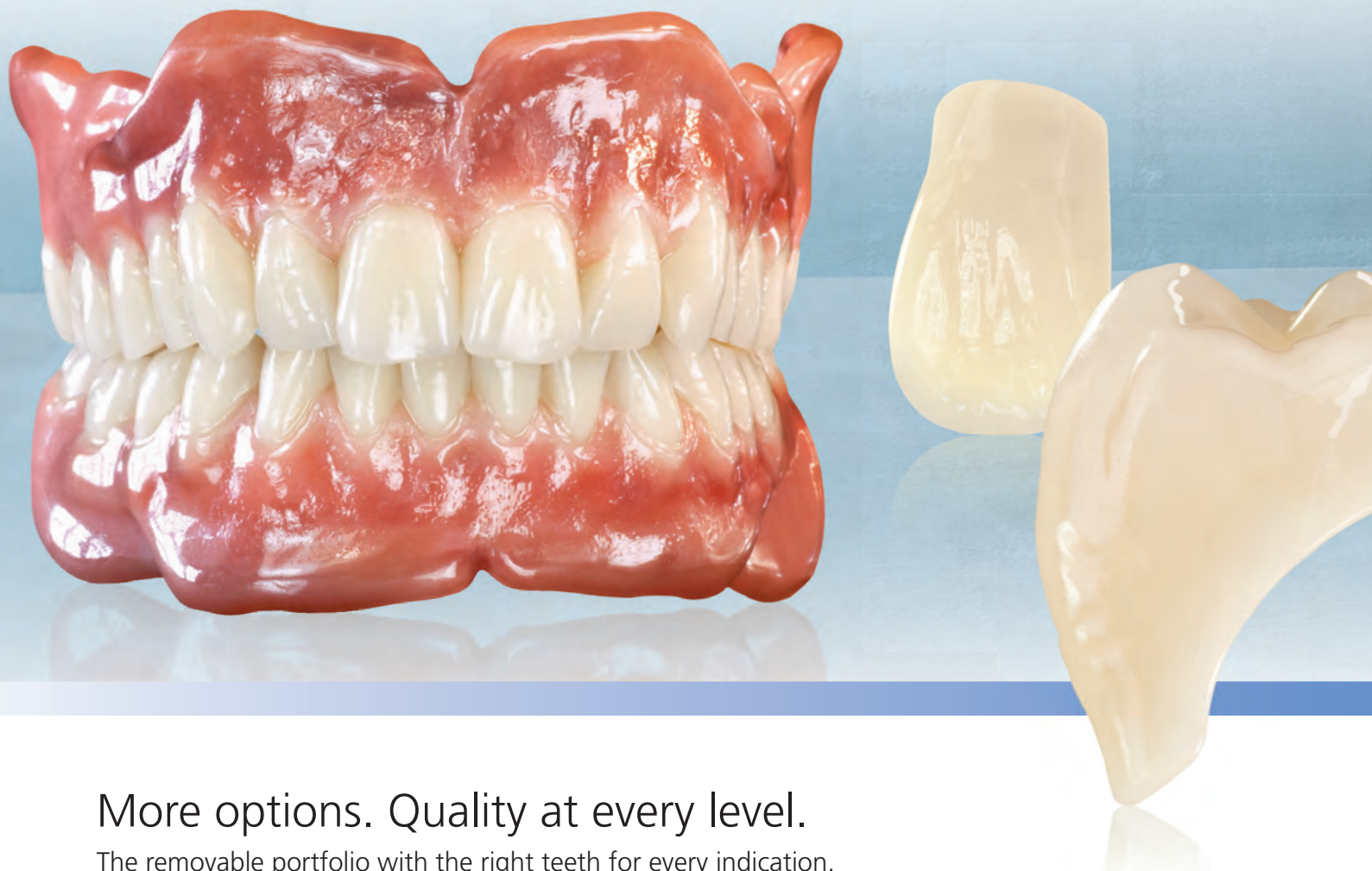

The foundation of this evolutionary step remains the unique **ASTRA TECH Implant System BioManagement Complex**, well-documented for its long-term marginal bone maintenance and esthetic results. www.dentsplyimplants.com



IVOCLAR VIVADENT REMOVABLE

More than dentures.



More options. Quality at every level.

The removable portfolio with the right teeth for every indication.

- ▶ **Master Class:** Phonares® II and PhysioStar® - The ultimate in function and esthetics
- ▶ **Premium:** BlueLine® and TCR™ - High performance and esthetics
- ▶ **Mid-Line:** - Vivodent® S - The perfect blend of value and esthetics
- ▶ **Entry Level:** Ivostar® Gnathostar® - Simple and efficient

All Ivoclar Vivadent and Candulor teeth are backed by our 100% Satisfaction Guarantee!

Contact your Ivoclar Vivadent representative to discuss which options are best for you.

100% CUSTOMER SATISFACTION
GUARANTEED!



ivoclarvivadent.com

For more information, call us at 1-800-533-6825 in the U.S., 1-800-263-8182 in Canada.
© 2014 Ivoclar Vivadent, Inc. Ivoclar Vivadent, BlueLine, Ivostar, Gnathostar and Phonares are registered trademarks of Ivoclar Vivadent, Inc. PhysioStar and TCR are trademarks of Candulor AG.

ivoclar
vivadent[®]
passion vision innovation