

# ACP MESSENGER

Summer 2014

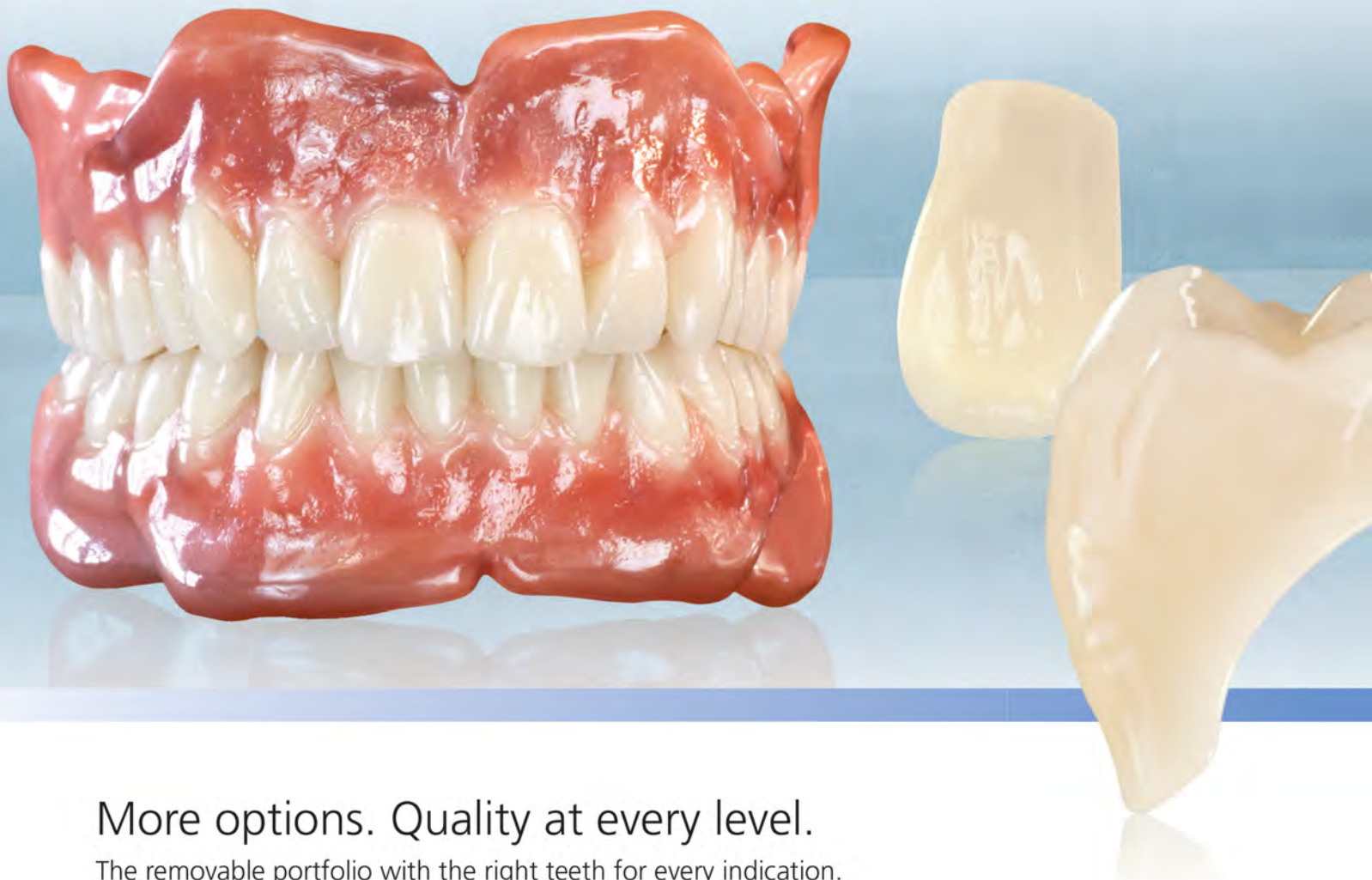Restoring natural smiles  
A life-altering change  
Beauty and hygiene

**ACP**  
AMERICAN COLLEGE OF  
PROTHODONTISTS

Your smile.  
Our specialty.®

# IVOCLAR VIVADENT REMOVABLE

*More than dentures.*



## More options. Quality at every level.

The removable portfolio with the right teeth for every indication.

- ▶ **Master Class:** Phonares® II and PhysioStar® - The ultimate in function and esthetics
- ▶ **Premium:** BlueLine® and TCR™ - High performance and esthetics
- ▶ **Mid-Line:** - Vivodent® S - The perfect blend of value and esthetics
- ▶ **Entry Level:** Ivostar® Gnathostar® - Simple and efficient

*All Ivoclar Vivadent and Candulor teeth are backed  
by our 100% Satisfaction Guarantee!*

*Contact your Ivoclar Vivadent representative  
to discuss which options are best for you.*

100% CUSTOMER SATISFACTION  
GUARANTEED!



[ivoclarvivadent.com](http://ivoclarvivadent.com)

For more information, call us at 1-800-533-6825 in the U.S., 1-800-263-8182 in Canada.  
© 2014 Ivoclar Vivadent, Inc. Ivoclar Vivadent, BlueLine, Ivostar, Gnathostar and Phonares are registered  
trademarks of Ivoclar Vivadent, Inc. PhysioStar and TCR are trademarks of Candulor AG.

**ivoclar**  
**vivadent**<sup>®</sup>  
passion vision innovation



*I used to think about that bike accident every time I looked in the mirror. I was a girl when it happened – my jaw was fractured and two of my teeth were knocked out. After the initial treatment, I could talk and chew, but my comfort and self-confidence never came back. I didn't think I would ever be happy with the way I looked. Years later, I found a prosthodontist who created a treatment plan to recover what I lost. Now, I feel like myself again – and I can't stop smiling.*

## In Every Issue

- 6 From the Editor: Esthetics and technology in unison
- 8 Case Presentation: Beauty and hygiene
- 10 In the Office: A life-altering change
- 14 At the Chair: Advanced digital technologies
- 16 In the Lab: Restoring functional beauty
- 19 For the Patient: Q&A: Restoring natural smiles
- 30 Our Community
- 31 Announcements
- 31 Upcoming Events
- 32 Classified Ads

## Featured

- 20 From the ACP Leadership: Committees
- 22 Inside the ACPEF: Check the BOX!
- 24 Prosthodontic Champions: NPAW 2014
- 27 Leading the Industry: Innovation
- 28 Annual Session Update

**Editor-in-Chief**

Jacinthe M. Paquette, D.D.S., F.A.C.P.

**Associate Editors**

Carl F. Driscoll, D.M.D., F.A.C.P.  
Frank J. Tuminelli, D.M.D., F.A.C.P.

**Editor Emeritus**

Lyndon F. Cooper, D.D.S., Ph.D., F.A.C.P.

**ACP Board of Directors**

John R. Agar, D.D.S., M.A., F.A.C.P., President  
Frank J. Tuminelli, D.M.D., F.A.C.P., President-Elect  
Carl F. Driscoll, D.M.D., F.A.C.P., Vice President  
Susan E. Brackett, D.D.S., M.S., F.A.C.P., Secretary  
Julie A. Holloway, D.D.S., M.S., F.A.C.P., Treasurer  
Lee M. Jameson, D.D.S., M.S., F.A.C.P., Immediate Past President  
Nadim Z. Baba, D.M.D., M.S.D., F.A.C.P., Regional Membership Director – Pacific  
Douglas G. Benting, D.D.S., M.S., F.A.C.P., Director, Prosthodontic Practice & Patient Care Division  
Lars Bouma, D.D.S., M.S., F.A.C.P., Regional Membership Director – Central  
Lino P. Calvani, D.D.S., M.Sc., F.A.C.P., Regional Membership Director – International  
Alan B. Carr, D.M.D., M.S., F.A.C.P., Director, Education & Research  
Nancy Deal Chandler, R.H.I.A., C.A.E., C.F.R.E., Executive Director  
David A. Felton, D.D.S., M.S.D., F.A.C.P., Editor-in-Chief, Journal of Prosthodontics  
Lily T. Garcia, D.D.S., M.S., F.A.C.P., Chair, ACP Education Foundation  
Gerald T. Grant, D.M.D., M.S., F.A.C.P., Regional Membership Director – Federal Services  
David L. Guichet, D.D.S., F.A.C.P., Director, Continuing & Professional Education  
Stephen I. Hudis, D.D.S., F.A.C.P., Regional Membership Director – Northeast  
Mark C. Hutten, D.D.S., M.S., F.A.C.P., Director, Forum  
Paul E. Scruggs, D.D.S., P.A., Regional Membership Director – Eastern  
Robert M. Taft, D.D.S., M.S., F.A.C.P., Director, Maxillofacial Prosthetics  
Victoria A. Vickers, D.D.S., Director, Public Relations & Communications Division  
Alvin G. Wee, D.D.S., M.S., M.P.H., Regional Membership Director – Rockies/Plains

**ACP Central Office Staff**

Nancy Deal Chandler, R.H.I.A., C.A.E., C.F.R.E., Executive Director  
Carla Baker, M.B.A., C.A.E., Associate Executive Director, Membership Services & Outreach  
Carolyn Barth, Director, Media Relations  
Mark Heiden, Director, Communications & Marketing  
Melissa Kabadian, M.A., C.M.P., Director, Education & Meeting Services  
Jack Kanich, Finance & Administration Manager  
Justin McDaniel, Administrative Coordinator  
Adam Reshan, Membership Services Manager  
Lauren Swanson, Communications & Marketing Coordinator  
Nathalie Williams, Sections & Governance Manager

**Managing Editor**

Mark Heiden

**Editorial Coordinator**

Lauren Swanson

**Design**

Publications Associates, Inc.

**Display Advertising**

Gennifer Kelling, M.J. Mrvica Associates, Inc.  
Phone: (856) 768-9360  
Email: gkelling@mrvica.com

**Classified Advertising**

Visit the 'Members and Dental Professionals' section at GoToAPro.org to download an insertion form. Email or fax the completed form to Lauren Swanson at lswanson@prosthodontics.org or (312) 573-1257. Classified ads are \$100 for the first 50 words and \$1 for each additional word for ACP members. The non-member rate is \$200 for the first 50 words and \$2 for each additional word. The minimum charge is \$100. Logos are an additional \$50, limited to one per ad and subject to approval. Payment by check, American Express, Visa, or Mastercard is required prior to placement.

The mission of the ACP Messenger is to inform readers about current prosthodontic trends, challenges, and successes. Statements of fact and opinion are the responsibility of the authors alone and do not imply an opinion on the part of the officers or the members of the ACP.

The ACP Messenger annual subscription rate for members is \$45, which is included in membership dues. The U.S. subscription rate for Prosthodontic Forum Organization members is \$55 and \$65 for non-members. Canadian subscribers add \$5 each year; all other non-U.S. subscribers add \$10 each year.

The ACP Messenger (ISSN # 0736-346X) is published four times per year in the winter, spring, summer, and fall by the American College of Prosthodontists:

211 E. Chicago Ave., Suite 1000, Chicago, IL 60611  
Phone: (312) 573-1260; Fax: (312) 573-1257  
Email: acp@prosthodontics.org  
Website: GoToAPro.org

© Copyright 2014 American College of Prosthodontists. All rights reserved. Materials may not be reproduced or translated without written permission. Contact the ACP for reprint permission.

Postmaster: Send address changes to the ACP Central Office at 211 East Chicago Avenue, Suite 1000, Chicago, IL 60611 or acp@prosthodontics.org.



**Dr. John Agar** is President of the ACP, and Assistant Program Director of Graduate Prosthodontics in the Department of Reconstructive Sciences at the University of Connecticut Health Center School of Dental Medicine.

► Page 20



**Dr. Avinash S. Bidra** is Program Director and Maxillofacial Prosthodontist at the University of Connecticut Health Center, Department of Reconstructive Sciences, Division of Prosthodontics. He serves as Chair of National Prosthodontics Awareness Week.

► Page 24




**Mr. Vincent Devaud** is a Swiss Master Ceramist with more than thirty years of experience. His design center is located in Pasadena, California.

► Page 16



**Dr. Carl F. Driscoll** is Program Chair of the 2014 Annual Session, Vice President of the American College of Prosthodontists, and Program Director for the Department of Prosthodontics at the University of Maryland.

► Page 28



**Dr. Lily Garcia** is Chair of the ACP Education Foundation and Associate Dean for Education at the University of Iowa College of Dentistry & Dental Clinics.

► Page 22



**Capt. Gerald T. Grant** is Director of Craniofacial Imaging Research at the Naval Postgraduate Dental School and Service Chief of the 3D Medical Applications Center, Department of Radiology, Walter Reed National Military Medical Center.

► Page 14



**Mr. Don L. Waters** is the President & Chief Executive Officer of Brasseler USA, a leading dental instrumentation company. Mr. Waters was named an Honorary Director of the ACP Education Foundation in 2013.

► Page 27



**Dr. Christopher B. Marchack** is an associate clinical professor at the USC School of Dentistry. He maintains a practice in Pasadena, California.

► Page 10



**Dr. Jacinthe M. Paquette** is recognized internationally as a leader and educator in prosthodontics, esthetics, and implant dentistry. She maintains a private practice in Newport Beach, CA.

► Page 6



**Dr. Gary S. Solnit** maintains a full-time private practice in Beverly Hills, which is limited to prosthodontics and implant dentistry. He is currently Director of the West Coast ITI Study Club.

► Page 8

# ACP2014

## PROSTHODONTICS

44TH ANNUAL SESSION • NOV. 5-8 • NEW ORLEANS

The meeting  
where solutions  
get real.



DIGITAL DESIGN

ADVANCED MATERIALS

MULTIDISCIPLINARY APPROACHES

Hyatt Regency  
New Orleans  
Nov. 5-8, 2014  
[acp44.com](http://acp44.com)

### WEDNESDAY

Advances in Maxillofacial Prosthetics

### THURSDAY

Complications and Treatment from Our Co-Specialists  
Diagnostic Considerations and the Legal Consequences  
That Follow

### FRIDAY

Complications, Failures, and Solutions in Prosthodontics

### SATURDAY

Clinical Complications, Innovative Laboratory Solutions

REGISTER BY SEPT. 26 AND SAVE!

# Esthetics and technology in unison

Jacinthe M. Paquette,  
D.D.S., F.A.C.P.  
ACP Messenger Editor-in-Chief

Prosthodontics has reached a place where esthetics and technology coincide almost seamlessly at a level and a pace never imagined before.

For this issue, we envisioned a focus on Esthetics in prosthodontic rehabilitations. However, as we selected the treatments to share with you, it became apparent that Technology is now an integral part of those rehabilitations, too. We can't talk about one without the other.

These advancements continue to enhance our treatment capabilities for precision in planning and precision in fabrication of restorations. This, in combination with the artistic and technological talents of our dental technology colleagues, allows for sound and beautiful treatment outcomes in even the most challenging of situations.

In his article, Dr. Gerald Grant addresses this "boom in digital dental solutions" and the issues surrounding it. He envisions prosthodontists taking a lead role in collaborating with industry to facilitate the functionality and ease of use of CAD/CAM systems. We want the systems to work the way we work – and do the things we, as prosthodontists, want them to do.

As prosthodontists, we are perfectly positioned to take the lead in oral-facial esthetics. Our advanced training provides the foundation. Dr. Gary Solnit will demonstrate how knowledge and understanding of oral-facial esthetics can assist with developing the most complementary esthetic outcomes in the dental rehabilitation patient. Minor changes in the replacement of the oral hard and soft tissues can result in profound esthetic enhancement and beauty of the final result.

Dr. Chris Marchack will demonstrate the state of the art in the delivery of a patient's rehabilitation, utilizing digital CT data for appropriate surgical planning synergistically with the completion of the final restorations through CAD/CAM technology and state of the art porcelain/ceramic systems.

---

Esthetics and technology can also bring about true life-changing transformations, with treatment that is carefully planned and orchestrated from beginning to end.

---

Of course, behind every successful rehabilitation are the efforts of a laboratory technologist to create lasting and esthetic restorations. Mr. Vincent Devaud is one such gentleman. As you will see, his skill, dedication, and training assisted in transforming a patient's tragedy to a functionally sound and esthetically pleasing outcome.

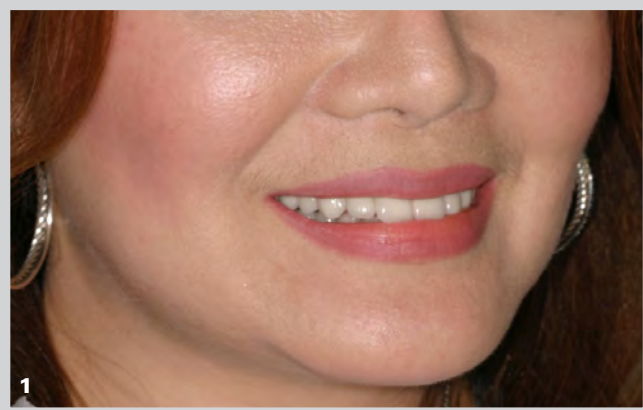
We hope this issue will reveal new possibilities for our services to patients in need, and that it may provide inspiration for sound and beautiful treatment outcomes of your own. ■



# Beauty and hygiene

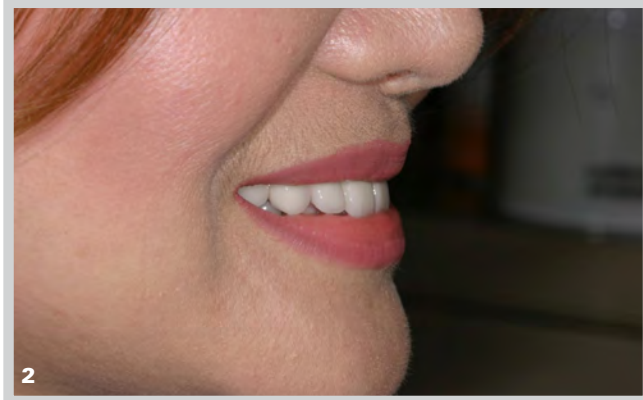Gary S. Solnit, D.D.S., M.S.

A 47-year-old woman visited my office with two concerns: the “flat” appearance of her face and difficulty cleaning around her maxillary fixed prosthesis.



She had implant-supported fixed prostheses in the maxilla and mandible. Both jaws had been restored approximately one year before our first consultation. The lack of maxillary lip support left her unhappy with the way her face looked.

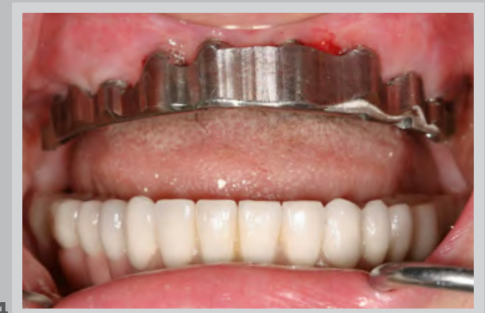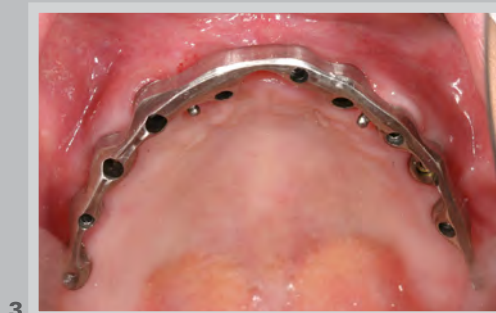She brought photos of herself when she was younger and had a complete denture. In the old photos, it was evident that she had more lip support from the extensions of the conventional denture and that the existing fixed prosthesis did not provide adequate support. (Fig. 1)



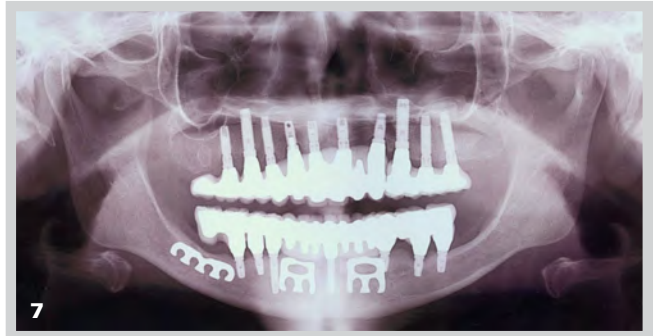With the existing fixed prosthesis, her upper lip folded over the top of the porcelain and gave her lip a flattened appearance. (Fig. 2)

The decision was made to convert the prosthesis to a fixed-detachable spark erosion prosthesis that would provide her with the function of a fixed prosthesis and give her the lip support needed.

Having the detachable design would also allow her to remove the prosthesis and clean properly around the connecting bar. (Figs. 3,4,5,6)





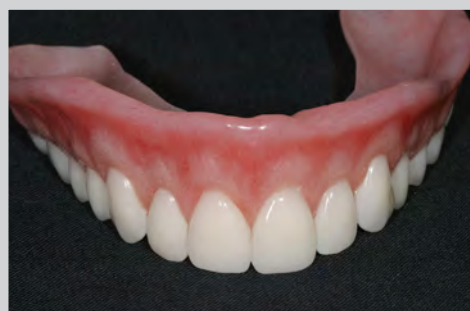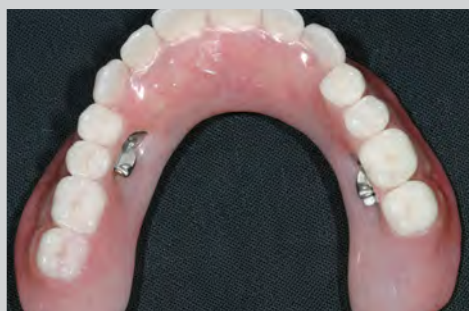

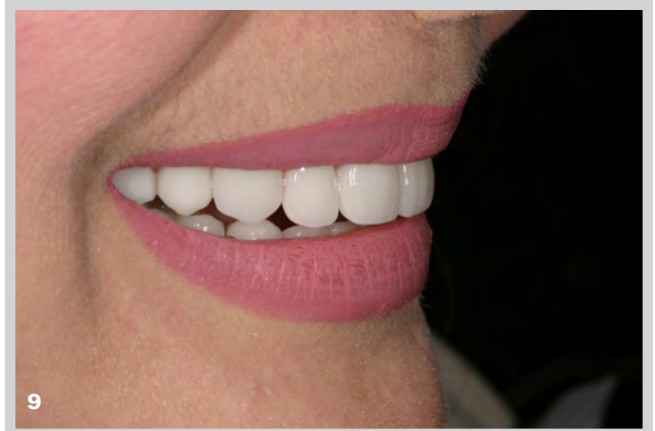
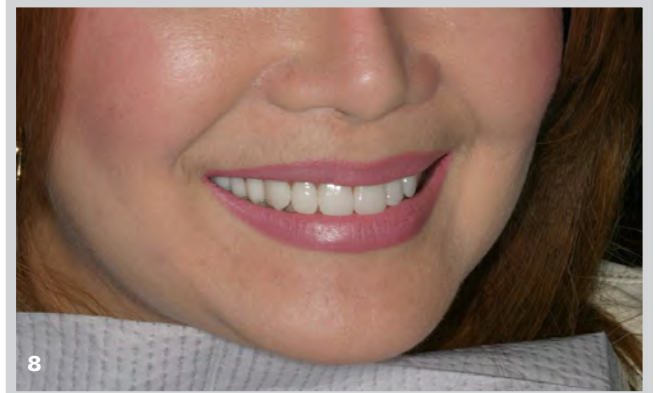During the wax try-in appointment, it was confirmed that with a removable prosthesis, adequate lip support could be attained and the upper lip appeared more natural.

A maxillary connecting bar was milled and screw retained to the 10 maxillary implants. The milled walls of the connecting bar were long enough to provide the overdenture with good resistance to forces and the embrasures were opened as much as possible to promote good oral hygiene.

The swinging latches were spark eroded (DAL Laboratories, Peoria, Illinois). A horseshoe-shaped overdenture was fabricated with a cast internal metal framework.

With the fixed detachable design, the patient was given better lip and facial support, while providing for better hygiene access. (Figs. 7,8,9) ■



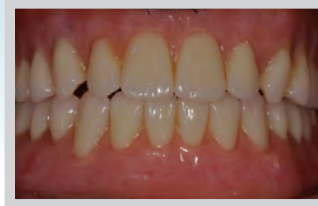# A life-altering change

Christopher B. Marchack, D.D.S.

One patient's journey from the decision to treat his failing dentition was a life-altering change. He was an established professional climbing the corporate ladder, but his aspirations were falling short because of his teeth.

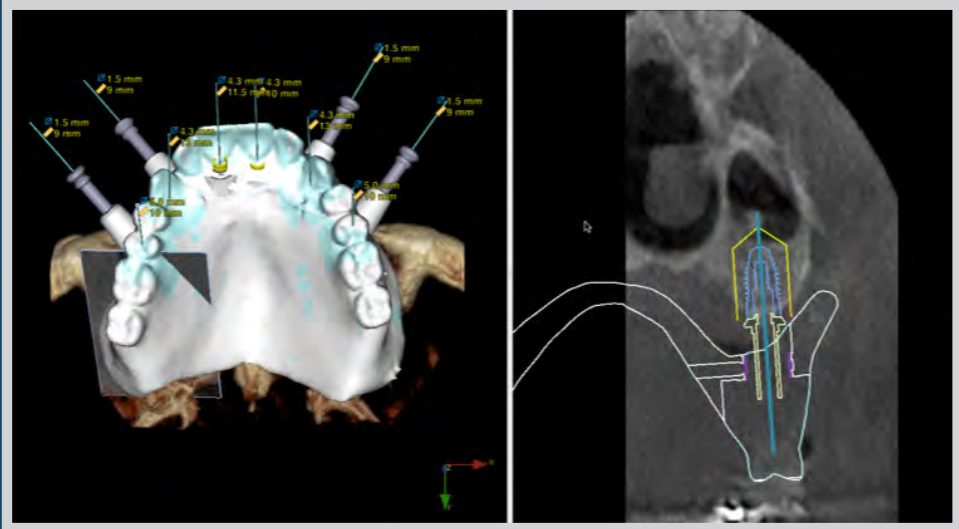
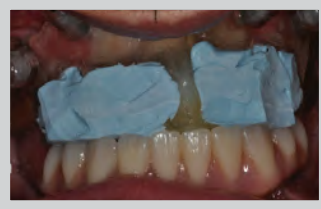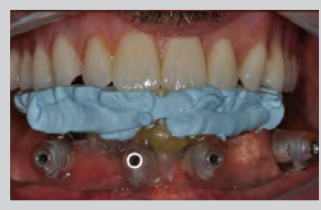Years of neglect developed into feelings of shame and caused a lack of confidence until he decided to make a change, beginning with seeing a prosthodontist.

After initial diagnosis, it became clear that all his teeth had to be lost. Immediate complete dentures were fabricated and inserted after complete extractions. The immediate dentures became the initial outline for designing his smile for speech and function. This initial outline of the tooth display also gave the matrix for implant planning and treatment. After the healing of the extractions, a refit procedure was completed and a cone beam CAT scan was completed.



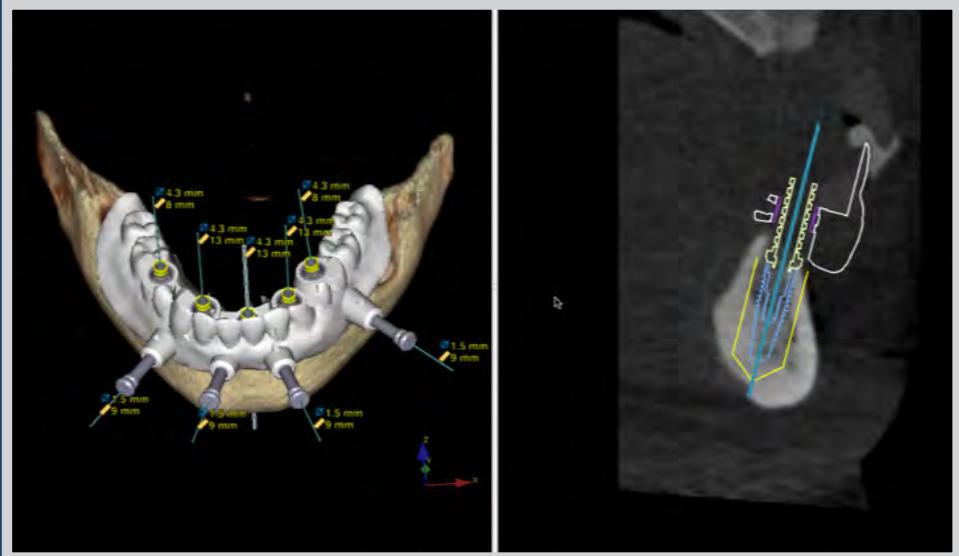
**Fig. 1:** The complete dentures were used as radiographic templates which outline the tooth positions in the surgical planning software.

A dual scan technique was used to understand the tooth positions and possible implant positions, in NobelClinician™, a three dimensional surgical planning software. Six implants were planned for the maxillae and five for the mandible, with complete understanding of the patient's anatomy as well as the restorative tooth positions. From the CAD/CAM surgical template, a working cast was



**Figs. 2 & 3 (Above):**  
The fabricated maxillary and mandibular CAD/CAM guided surgical templates with a surgical index that locates the position of the surgical template.

**Fig 4 (Top, right):**  
The maxillary surgical plan in the NobelClinician™ software. Six implants were planned with four horizontal guided anchor pins that help retain the surgical template during implant surgery.



**Fig. 5 (Bottom, right):**  
The mandibular implant planning for five implants, with the ideal long axis and draw for the fabrication of the prosthesis.

fabricated with the planned implant positions. On the working casts, maxillary and mandibular acrylic resin provisional restorations were made prior to the actual implant placement. This made the immediate load procedure more predictable and less time consuming for the clinician and patient. The implant surgical procedure was completed using a flapless technique, which was possible due to the precision of the guided surgical technique.

Initially, the patient was advised not to chew on the prostheses while integration of the implants began. Gradually after weeks of healing, he was allowed to chew soft foods and then enjoy a normal diet. These provisional restorations guided the healing of the soft tissue and assisted in evaluating the patient's speech and esthetics. Once complete healing occurred, the provisional restorations were duplicated to begin the designs of the definitive prostheses.

Acrylic resin scanning appliances were fabricated and tried in to evaluate and confirm the patient's smile line, overall esthetics, and speech.

After approval of these appliances, they were used in a dual scan technique with a NobelProcera 2G scanner to duplicate and create an all-zirconia CAD/CAM prostheses. The prostheses were milled from a solid piece of zirconia, tried in to confirm the fit and seat to the implants. A solid lingual zirconia design was used to minimize the placement of any veneering porcelain.

This digital workflow allowed for precise implant placement, planned with the ideal restorative positions, through a minimal invasive surgical technique, and minimized the multiple laboratory steps to create the definitive zirconia restorations. The final results of the screw-retained all-zirconia fixed complete denture prostheses changed the patient's smile, function, confidence, and quality of life. ■

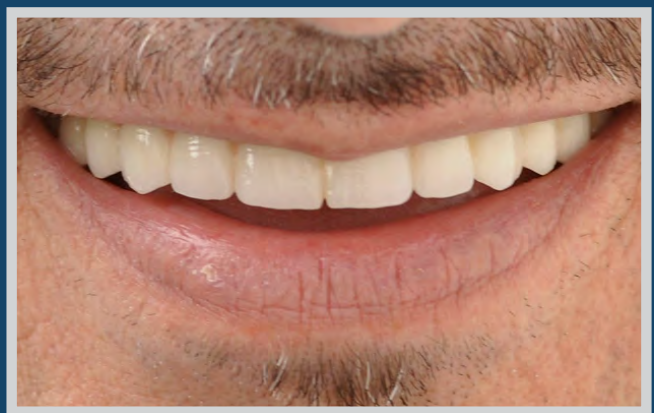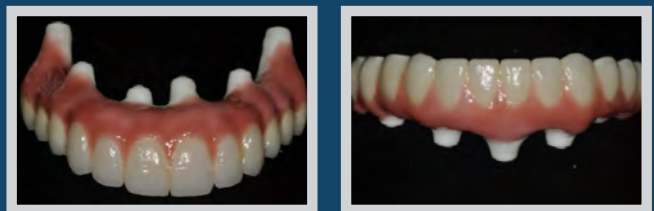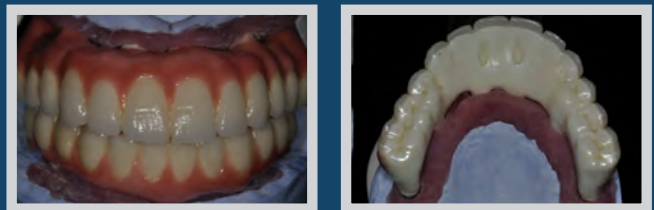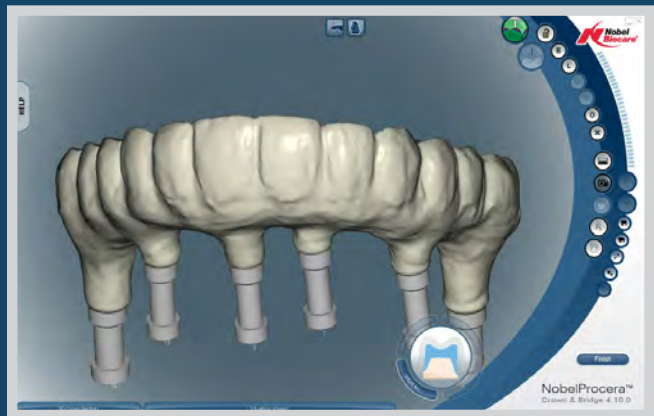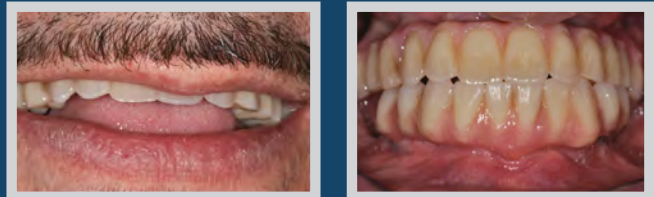*The author would like to thank his in-office ceramists Raymond Tran and Rosana Kamiyama for their dedication, diligence, and excellent skills.*

**Figs. 7 & 8 (Top):** The prefabricated provisional restorations that were inserted at the time of implant surgery.

**Fig. 9:** The double scan of the maxillary prosthesis appliance and the verified implant positions.

**Figs. 10 -13:** The milled zirconia implant restorations with facial veneering porcelain and pink gingival tissues.

**Fig. 14:** The patient's smile after insertion of the definitive prostheses.



A detailed historical illustration of Chicago in 1868, showing the city's layout along the Lake Michigan waterfront. The city is densely packed with buildings, and the water is filled with numerous sailing ships and steamships. The text 'CHICAGO' is written in large, bold letters at the bottom left, and 'IN 1868.' is at the bottom right. A small circular inset shows a different view of the city.

It's time for an update.

# Prosthodontic Review Course

Sept. 12-13, 2014 • Chicago

This two day course describes prosthodontic treatment approaches that meet esthetic and functional goals expected by patients and clinicians. The course also outlines key concepts based on evidence that interweaves diagnosis and planning with treatment. Results are expected to provide confidence in treatment predictability.

## Who Should Attend?

This course is intended for practitioners who would like to stay up to date on the latest trends as well as prosthodontists who want to become board certified, residents who are taking the board exam, and dental professionals who are interested in the specialty.

## Location

Loyola University  
Water Tower Campus - Kasbeer Hall  
25 E. Pearson St.  
Chicago, IL 60611

## Course Director

Steven J. Sadowsky, D.D.S., F.A.C.P.  
University of the Pacific

## Registration Information

Register online at [GoToAPro.org](http://GoToAPro.org)  
\$895 Members  
\$395 Students/Residents  
\$995 Non-Members

## Continuing Education Credit

This course has been approved for 15 credit hours.

## Speakers

Steven J. Sadowsky, D.D.S., F.A.C.P.  
University of the Pacific, Department of Integrated Reconstructive Sciences

Julie A. Holloway, D.D.S., M.S., F.A.C.P.  
University of Iowa, College of Dentistry

Kent L. Knoernschild, D.M.D., M.S., F.A.C.P.  
University of Illinois at Chicago, College of Dentistry

Charles J. Goodacre, D.D.S., M.S.D., F.A.C.P.  
Loma Linda University,  
Department of Restorative Dentistry

J. Robert Kelly, D.D.S., M.S., D.Med.Sc.  
University of Connecticut Health Center,  
School of Dental Medicine

Mathew T. Kattadiyil, D.D.S., M.D.S., M.S., F.A.C.P.  
Loma Linda University,  
Department of Restorative Dentistry

David G. Gratton, D.D.S., M.S.  
University of Iowa, College of Dentistry

Thomas J. Salinas, D.D.S., F.A.C.P.  
Mayo Graduate School of Medicine,  
Department of Dental Specialties

Thomas D. Taylor, D.D.S., M.S.D., F.A.C.P.  
University of Connecticut Health Center,  
School of Dentistry

Steven Eckert, D.D.S., M.S.D., F.A.C.P.  
Clear Choice Dental Implant Center, Edina, Minnesota

Brian Kucey, D.D.S., M.S.Ed., F.R.C.D., F.A.C.P.  
Kucey Dental Group, Edmonton, Alberta, Canada

Jeffrey E. Rubenstein, D.M.D., M.S., F.A.C.P.  
University of Washington, School of Dentistry

Clark M. Stanford, D.D.S., Ph.D.  
University of Iowa, College of Dentistry

**ACP**  
AMERICAN COLLEGE OF  
PROSTHODONTISTS

Your smile.  
Our specialty.®

# Advanced digital technologies

Gerald T. Grant,  
D.M.D., M.S., F.A.C.P.

There has been a boom in digital dental solutions with advances in the technology around every corner. Faced with a shortage of skilled dental laboratory technicians in the United States, alternative methods that provide dental prostheses in a timely manner are becoming more attractive.

As computer assisted design/computer assisted manufacturing (CAD/CAM) and other Direct Digital Manufacturing (DDM) techniques become more advanced, the skills of the dental laboratory technician will need to be redefined, with greater knowledge in computer design and digital manufacturing replacing traditional craftsman skill sets. This move from skilled craftsman methodology to digital workflow has already shifted into use in some larger labs to increase productivity, offsetting the shortage of laboratory services by reducing the number of technicians required.

Although these digital systems were originally intended for chair-side fabrication of simple restorations, the complexity of the technologies has begun to provide opportunities for use in more complicated restorative cases. Laboratory software has “simulated” articulators based on existing articulators; larger milling machines can mill full arch restorations; and additive manufacturing technologies have been adapted to provide metal frameworks for full metal restorations and ceramic applications. Similarly, registration algorithms now provide the ability to accurately relate opposing arches, as well as CT Scans and 3D photographs to each other. These advancements have contributed to the development of virtual surgical simulations from digital scans and medical imaging technologies essential for planning surgical guides, provisional restorations, and final restorations from pre-surgical planning to final restoration. Furthermore, emerging navigation systems may soon be able to track the full range of jaw movement, which could be incorporated into the



restoration design and lead to the demise of dental articulators.

Restorative materials have new requirements, limited (or unlimited) by milling and additive manufacturing technologies. Traditional metals and ceramics may give way to new polymers, eutectic metals, and composite materials that are more appropriate for CAM technologies with better fit, esthetics, wear resistance, and longevity. Extra-oral prosthetic materials will provide the ability to digitally design and directly “print” prostheses, allowing for layered coloring, and multi-material manufacturing to provide more lifelike support and function. Systems for indirect scanning and milling of completed dentures have recently been introduced to the market.

Impression techniques have been replaced with digital image captures. Traditional stone casts can be scanned; impressions can be scanned; camera systems and medical imaging are used for extra-oral captures; and intra-oral scanning technology continues to

improve at an alarming rate, with a steady stream of new systems becoming available. Powdering of surfaces has been replaced by non-powdered scanning and color scanning; it is not difficult to believe that soon we will not need to even see the preparation margins to capture an acceptable image. Presently we have static capture; however, with the advent of milled dentures, there may be a need for dynamic direct capture techniques of soft tissue, or even a new philosophy of impression technique. Stepping away from the traditional laboratory requirements for restorations, as scanning technologies improve, there will be no need for an articulated cast of the prepared teeth or abutments, and restorations will only arrive from the laboratory for delivery to the patient.

There are new terms that are not part of the “Glossary of Prosthodontics”, such as “shell”, “polygons”, and “wire mesh” that are used in CAD or “load platform”, “milling axis”, and “water tight” with CAM. Unlike the traditional review of material properties, techniques, and philosophies behind the procedures, present dental school curricula do not address the basics of the digital processes of scanning, design, and computer manufacturing technologies. There may be limited commercial sponsorship exposure to specific systems in some undergraduate programs, but it would be interesting to assess the extent of the exposure in specialty training programs.

Technologies now exist to treatment plan, design surgical guides for implant placement or to cut or position bone, develop restorative designs, and computer manufacture all of the support needed from digital images of the patient. In addition, you can combine many of these procedures from a single restoration on a tooth or implant to placement and restoration of multiple implants, teeth, and dentures. All of this can be accomplished with minimal patient pre-treatment contact, via digital imaging and a combination of design software and computer manufacturing that can result in the pre-treatment design and manufacturing of the final prosthesis.

In an effort to address and introduce many of these concepts, we have recently begun to see corporate-sponsored symposia on the use of digital dental systems. Although many speakers are well-versed in the use of “digital dentistry” workflow, materials, and case presentations, there is very little from professional organizations in the discussion of how we understand the concepts, evaluate the materials and methodology, and develop practice philosophies that guide the use of digital technologies in patient care.

Digital technologies seem to be boundless, and will revolutionize how we provide restorative and diagnostic care for our patients. The American College of Prosthodontists – the leading specialty organization in oral reconstructions – must facilitate an open discussion as to how we, as prosthodontists are going to (1) develop a basic understanding of the technology and the implications it may have on our philosophies for dental restorations, (2) determine what functionality we want out of the systems, (3) accept these systems as part of our care in the restoration and diagnosis of our patient and, most importantly, (4) leverage this technology to strengthen our specialty.

Do we want to have some input into the continued development of this truly revolutionary change to our specialty, or do we want to continue to react to what the industries provide for us? We should consider an open and honest discussion to better define digital dentistry, to include what philosophical changes may need to occur to accommodate the technologies and what dental education requirements are necessary to ensure the effective use and application of the technologies in patient care, as well as development of criteria and openness to non-conventional materials to address our restorative needs, best workflow practices that accommodate patient treatment, provider accessibility, and business practices, and establishment of standards for industry. ■

# Restoring functional beauty

Vincent Devaud,  
C.F.C., M.D.T.

A young woman was involved in a car accident resulting in considerable facial trauma including lip lacerations, tooth loss, and surrounding facial bone loss.

Years ago, the initial attempts at correcting the traumatic loss of the teeth and bone had proven unsuccessful. After three surgical osseous ridge augmentations, soft tissue grafts, and implant placement procedures, she was left with a removable appliance for several years.

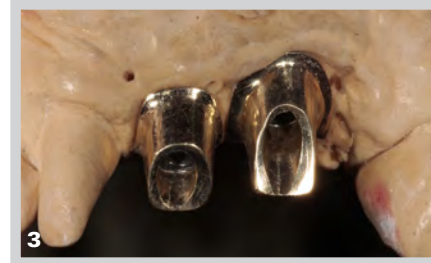
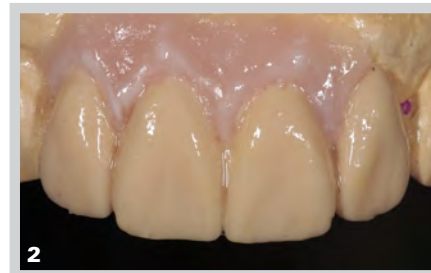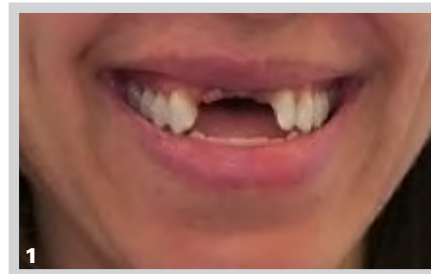
Recreating a natural, esthetically pleasing treatment outcome would require the expertise of a talented interdisciplinary team in such a challenging case, especially with the difficulty of creating both the pink and white sophisticated prosthesis.

## A treatment plan was created which included the following:

- Placement of two dental implants
- Panoramic x-ray review
- Both frontal and lateral smile photographs
- Digital photographic records establishing unobstructed dynamic views and retracted views
- Shade analysis
- Personalized smile design incorporating full contour wax up of the teeth and pink tissue relationship
- Custom removable appliance to simulate accepted wax up by the doctor and patient

## Final treatment:

- 2x Custom UCLA 4Degrees Tapered Milled Custom Abutments
- Porcelain-fused-to-metal suprastructure from #7-9
- Porcelain veneer on #10



**Fig. 1:** Auto accident resulted in the loss of three of the upper front teeth and significant loss of the surrounding hard and soft tissues.

**Fig. 2:** A diagnostic wax-up illustrates the planned replacement of the teeth and surrounding tissues.

**Fig. 3:** Custom designed gold implant abutments would serve as part of the retentive structures beneath the porcelain-fused-to-metal prosthesis.



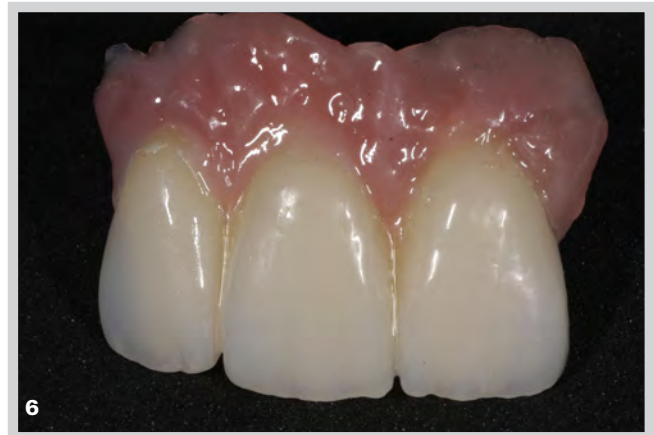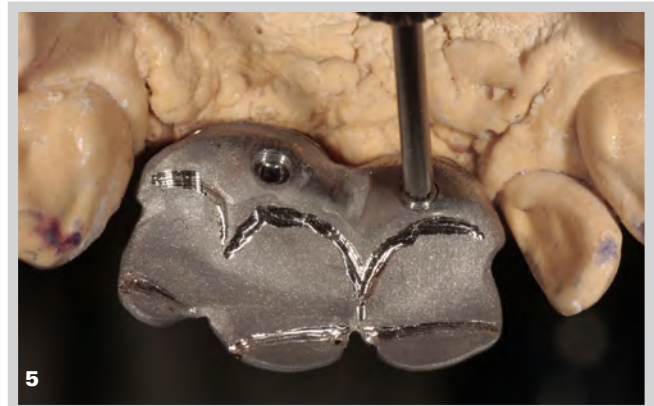
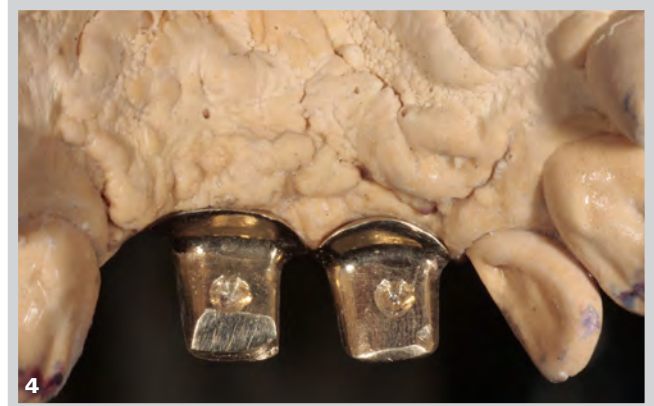To achieve her goals, the technique of a traditional fixed prosthetic implant-supported bridge was used. The missing bone and tissue volume was replaced with artificial pink porcelain, incorporating an undetectable white and pink relationship. This design also allowed for long-term functionality and retrievability.

A traditional PFM-casted framework was developed incorporating 2x lingual tapped Mini Swiss Screws in addition to a CO/CR Gold Island to reduce lingual porcelain stress fractures. Finally, gold design ovate pontic extended to the gingival facial aspect for optimal hygiene access and support of the pink porcelain and long-term health of the peri-implant tissues.

A porcelain veneer on tooth #10 was created to ensure the proper alignment of this tooth from its pre-operative mesial facial rotation and to conceal the compromised bone mesial defect.

A silicone record of the incisal position and facial esthetics of the accepted removable treatment partial denture was used as a guide for the final restorative goals. Pink porcelain was utilized to replicate the missing hard and soft tissues, and was created utilizing a blend of light and dark pink porcelain materials. In addition, the life-like appearance was enhanced with the use of a blend of custom white, yellow, violet, blue, and clear ceramic pigments to emulate the existing state of the natural gingival mucosa.

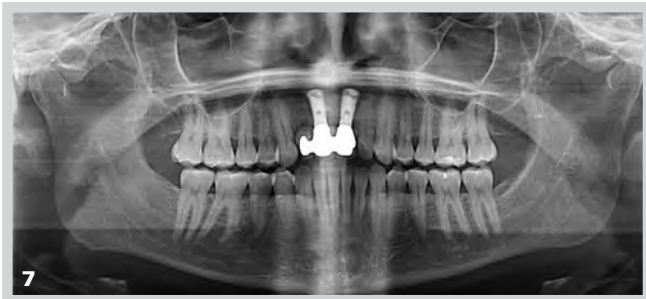Two years later, the patient continues to enjoy her restored beauty, and her dentist has full case retrievability to access periodical cleaning revision—and review and access the two custom implant abutments.



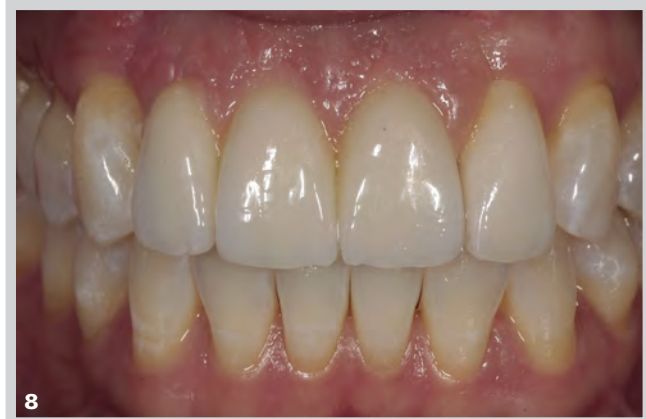**Fig. 4:** A lingual view of the gold abutments demonstrating the Mini Swiss Screw locations.

**Fig. 5:** Metal framework for the porcelain fused-to-metal prosthesis designed for lingual screw access and retrievability.

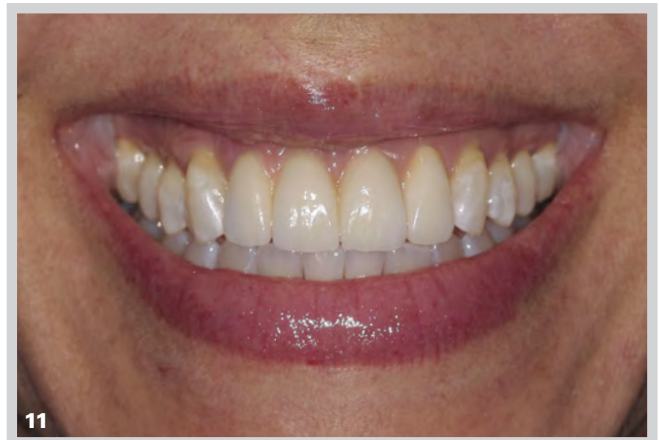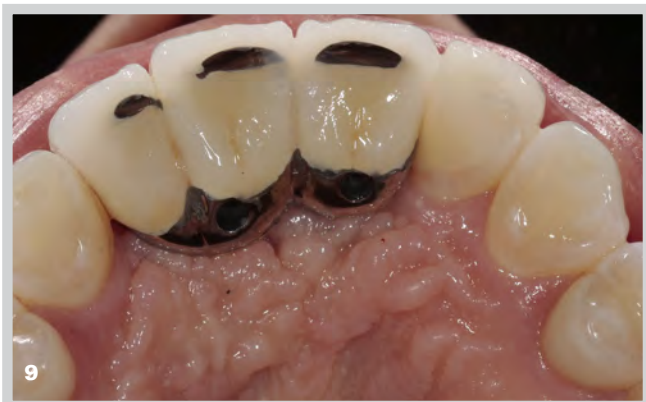**Fig. 6:** Completed prosthesis ready for delivery. Note the extent of the pink porcelain utilized to create an esthetically pleasing natural appearance.



The transparent outcome of this treatment was especially important in this patient with a high lip line. Patients often desire better esthetic outcomes and would like treatment alternatives that offer transparent esthetic results along with retrievability and longevity – and perhaps more importantly offer full closure and unrestricted enjoyment of their lives again.



Through comprehensive treatment plans and advanced materials, we can provide those outcomes. ■



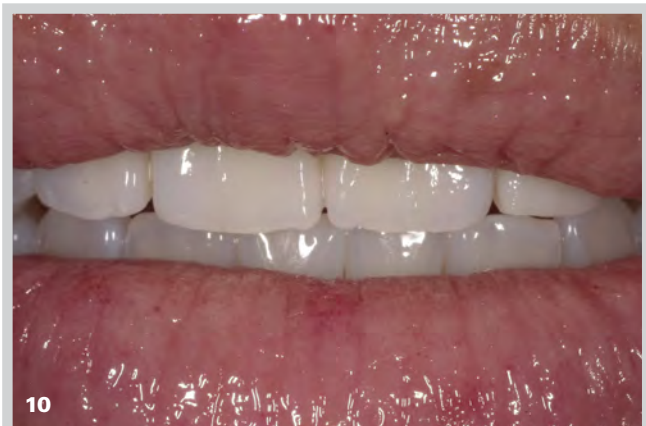**Fig. 7:** Panoramic radiograph with the final restoration in place.

**Fig. 8:** Close-up view of the natural and undetectable appearance to the implant rehabilitation.

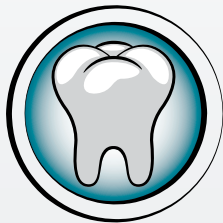**Fig. 9:** Lingual view of the prosthesis. Note the location of the screw accesses for ease of retrievability. Three gold lingual centric rests were created with the intention of protecting the patient's envelope of function and greatly reducing the risk of accumulated ceramic stress that would potentially result in future ceramic fractures.

**Fig. 10:** Complimentary tooth shades and form blend naturally with the patient's surrounding teeth.

**Fig. 11:** Patient can now smile in full confidence with a beautiful and successful treatment outcome.



## Q&A: Restoring natural smiles



### Q: What causes tooth discoloration?

A: Tooth discoloration may be caused by problems with the formation of the tooth enamel, problems within the tooth, or by stains from food, beverages, or habits such as tobacco use. Certain medications or chemicals taken by a pregnant woman or by a very young child can disrupt the development of tooth enamel and result in the tooth becoming discolored with gray bands, mottling, or pitting.

This type of tooth discoloration may be managed by a tooth whitening procedure and/or the placement of porcelain veneers. Tooth discoloration also may be caused by a tooth that is chronically infected or necrotic with the tooth taking on a uniform grayish hue. In this situation, the infection must be treated first and then the color can be corrected by bleaching or a restoration. Often a thorough professional cleaning will remove the discoloration and restore the teeth to their original brightness and whiteness.



### Q: How do prosthodontists restore smiles?

A: A prosthodontist has completed advanced training in the restoration of teeth to their natural form, color, and function. Esthetic restorations can help you achieve a more natural-looking smile and improve your teeth's natural beauty and strength. Prosthodontists can replace stained, chipped, missing, or worn teeth with inlays, crowns, veneers, bridges, and implants using the most advanced esthetic restorations to bring back your beautiful smile.



### Q: How can enamel shaping help?

A: Many people have an attractive smile with a few minor imperfections. Enamel shaping to correct these slight flaws can improve a person's perception of their smile. Enamel shaping can correct uneven edges of the front teeth or round off sharp pointed tips of the teeth and make the smile more proportioned and even. It is important that the smile has some "character" and has some slight unevenness to make it look more natural.



### Q: What might cause spots on my mouth or tongue?

A: Spots on your mouth or tongue can result from infection, causing swelling, redness, and ulcers (i.e. cold sore/herpes, gingivitis, thrush, chicken pox). Allergic reactions to food or other substances can cause red and white spots. Other causes include trauma, vitamin deficiencies (i.e. B12), antibiotics, smoking, canker sores, and cancer.

An examination of the mouth by your prosthodontist is necessary to determine the cause of the spots on your mouth or tongue. Treatment may include removal of the cause of trauma, antibiotics, anti-viral medication, anti-fungal medications, creams, rinses, and tongue scraping.

# Committees

John R. Agar,  
D.D.S., M.A., F.A.C.P.  
ACP President

The success of the American College of Prosthodontists depends on the creative efforts and professional commitment of so many people. Each of these volunteers is giving a gift that nobody else could give: the unique talents and expertise that they have earned through their advanced education and their years of experience.

They don't seek compensation for their work on behalf of the College, and we don't have the chance to publicly recognize all of them, though they all deserve it.

Some of the most substantial yet little-seen work to advance the specialty is done by members of ACP committees and task forces. Covering matters of awareness, advocacy, education, and more, these committees meet throughout the year to provide an important service to their fellow members.

For example, Dr. Hamilton Le is hard at work with the members of the Private Practice Committee to complete a new edition of the ACP's Private Practice Manual, which is a vital source of practical information to members in practice, especially young members. Dr. Stephen Bergen has gathered a talented group of people on the Membership Communications Committee to improve the text and images on the ACP's website, which is very helpful in our efforts to reach consumer audiences as well as our members. Dr. Steve Wagner and the Board Prep Study Committee are undertaking a major revision to the ACP Board Prep Study Guide, including adding material to make it more applicable for prosthodontists that are not recent graduates, which is one of our most important educational initiatives. Education and research committees provide recurring support that requires considerable effort.

The spirit of cooperation and camaraderie can be seen in many of these committees. Dr. Rick Williamson and his task force are working on a revision of the Prosthodontic Diagnostic Index. Their work is being coordinated with Dr. Terry Kelly's task force, which is tracking developments related to dental reimbursement programs and diagnostic codes applicable to the practice of prosthodontics.

There are also committees and task forces that arise due to timely needs and developments within the specialty. Dr. Carl Driscoll is leading a task force that is studying the impact of dental school debt on the career choices and workplace challenges of prosthodontics residents. Earlier in this issue of the Messenger, you saw an article from Dr. Gerald Grant, who is working with Drs. David Gratton and David Guichet to keep ACP members abreast of developments in digital dentistry and advanced technology.

I could fill several pages about the work being done by these and other committees. As ACP President, I am continually awed when I take a step back and look at the "big picture" of everything that volunteers are doing to support our specialty. As you continue to progress in your career, please consider ways in which you might be able to contribute. Wherever your talents and expertise may lie, there is a committee for you!



# It's time to practice.

Prosthodontic  
Practice  
Essentials

How are you going to bring patients through the doors of your new practice? What do you need to know about consent forms, human resources, marketing, insurance, and other issues you didn't study in school?

That's where the Prosthodontic Practice Essentials come in. Personally selected by experienced practitioners, these are the items that no prosthodontist's office should be without. Full of practical resources and information, the Prosthodontic Practice Essentials are designed to ensure you're ready for your first day in practice.

**Includes:**

- Nine Sets of Patient Education Brochures: Denture Care, Implants, Esthetics, Oral Cancer, and More
- Private Practice Manual
- 27 Proven Marketing Strategies to Boost Your Practice Profits
- 'Prosthodontist' Lab Coat

A value of more than \$700 -  
Only \$399 to ACP members!  
Order online at [GoToAPro.org](http://GoToAPro.org)

**ACP**  
AMERICAN COLLEGE OF  
PROSTHODONTISTS

Your smile.  
Our specialty.®

# Check the BOX!

Lily T. Garcia,  
D.D.S., M.S., F.A.C.P.  
Chair, ACP Education Foundation

When you renew your ACP membership, consider “checking the box” for your contribution to the future of the specialty through the ACP Education Foundation.

Dental students giving.....yes, I said dental students!

I had the privilege of giving the “speech” at the Georgia Regents University College of Dental Medicine, Class of 2014 Hooding Ceremony. Whether my “speech” was memorable or not, the more important note is to witness and literally feel the excitement of the day as our new colleagues join the profession. At this event, the Class President announced that his class of 2014, a total of 70 new, young dentists, pledged \$30,000 to their dental school. Everyone in the audience including me and fellow ACP member Dr. Carol A. Lefebvre, Dean of the dental school, were astounded at the amount!

I was intrigued by the culture of giving that the school has created. Despite the economy, despite the competition, it is the will and generosity of 70 young colleagues that spoke the loudest. That means that on average, each student set aside \$428.57 over their four years of dental school or a total of \$107.14 a year in order to reach this goal. This under the shadow of educational debts that many of us have difficulty pondering.

I ask you now. Prosthodontics as a specialty is vibrant in all sectors. I do not deny that the private practice of prosthodontics is challenging, but the care you provide for each individual patient is rewarding. As a prosthodontist, you change people’s lives, one person at a time, one solution for one patient at a time. Yes, many of us have lots of competing allegiances and



obligations. And yes, many of us are in the midst of our children in school, college, etc. But yet, we are looking to our colleagues, the residents in advanced education programs in prosthodontics and new prosthodontists in practice and other sectors, to carry the torch to advance the specialty. Help us have the impact on our future through the ACP Education Foundation.

When you renew your ACP membership, consider “checking the box” for your contribution to the future of the specialty through the ACP Education Foundation. If every single member “checked the box” to contribute each year, that would mean the ACPEF could support engaging many more of our prosthodontics residents and newer prosthodontist colleagues through support of their membership, attendance at our Annual Session for networking, and outstanding continuing professional education in prosthodontics – as well as support for the existence of our specialty through innovative research and scientific endeavors for the public.

Let’s imagine that there are two optional ACPEF donation boxes when you renew your membership, the \$100 box and the \$250 box.

---

If only our active ACP members “checked the \$100 box”, the ACPEF would have \$224,800 in one year to support the specialty.

If only our active ACP members “checked the \$250 box”, the ACPEF would have \$562,000 in one year to support the specialty.

---

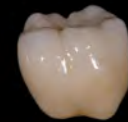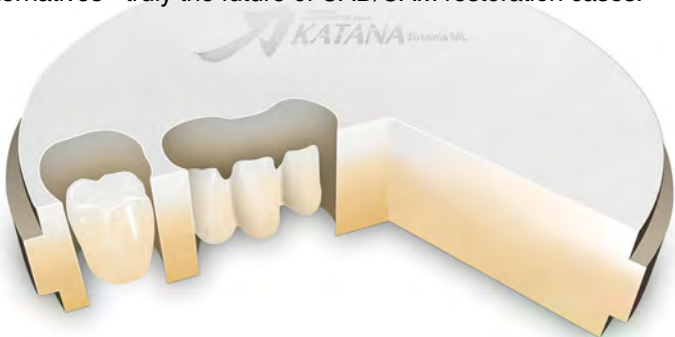
I want to extend my sincere gratitude to many of you... thank you for your generous donations since you are the members that exceed our hopes and asks! For those of you who are considering a donation to our ACP Education Foundation, start simple, start with what a dental student gave in one year: approximately \$100.

The possibilities are endless as I hopefully review the potential numbers; it is exciting NOW for our ACP Education Foundation and there is still so much more room for growth. Please consider checking the box! ■

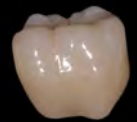## Could this be Full Zirconia?

Review our work samples at [www.cuspdental.com](http://www.cuspdental.com)

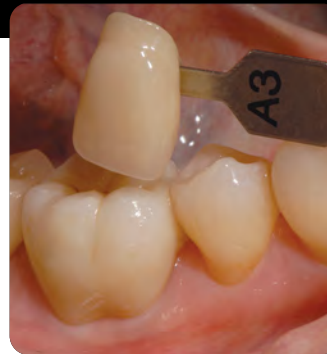Introducing new KATANA multilayered (ML) and HT Full Contour Zirconia (FCZ), now available at Cusp Dental. Obtain outstanding esthetics, durability, accuracy and high-translucency from this FCZ material. Ideal for metal-free posterior and anterior restorations, these are cost-effective and time-saving prosthetic alternatives - truly the future of CAD/CAM restoration cases.



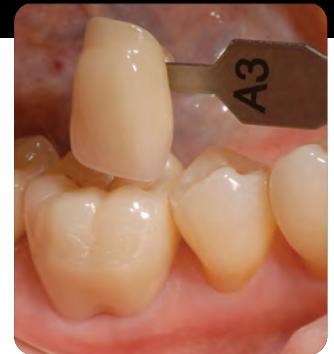A-Light: Stained



A-Dark: Polish only



ML: A-Light



ML: A-Dark

**KATANA multilayered (ML) Full Contour Zirconia**

381 Pearl Street, Malden, MA 02148 toll free/ 888-267-0660 781-388-0078 [info@cuspdental.com](mailto:info@cuspdental.com)



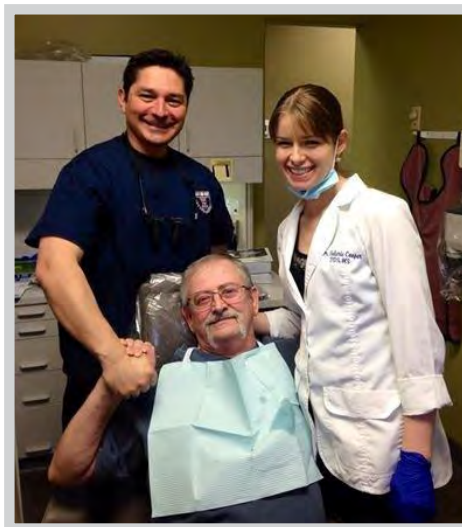# NPAW 2014: The largest celebration so far!

Avinash S. Bidra,  
B.D.S., M.S., F.A.C.P.  
NPAW Chair

This has been such a great year for National Prosthodontics Awareness Week (NPAW) that it makes a proud and fun experience to write this message! NPAW has historically been very successful in the academic setting (largely due to the contributions of Prosthodontics Residency Programs), but celebrations lacked the same fervor amongst private practitioners.

We made a decision for this year to channel resources toward energizing our private practice members. As such, we offered numerous exclusive tips and ideas for private practitioners to implement as part of NPAW. These ideas were disseminated through weekly emails as well as the NPAW toolkit. The Wednesday morning weekly emails preceding NPAW helped to remind members and maintain a momentum such that we saw the maximum amount of media engagement by members.

As you can imagine, garnering media interest in dentistry is not easy compared to sports, politics, or entertainment. However, prosthodontists and prosthodontics lend themselves to major oral health transformations and life changing treatments, which can be sensational enough to gather media attention in USA Today and TV news segments in four states!



Ohio: Drs. Cooper and Suarez-Sanchez made free dentures for 10 patients with complex treatment needs.

Of course, the purpose of NPAW is not only to gather media attention, but also to generate a greater level of recognition of prosthodontics and prosthodontists by dental students (read: future dentists), as well as our fellow medical and dental colleagues.

Like the public, most seasoned dentists (generalists and specialists) are not aware of the scope of modern prosthodontics and what prosthodontists do. Therefore, it is important to raise awareness of prosthodontics as a year round event and use

NPAW as a week where we can all synchronize our most exciting activities to celebrate prosthodontics together, nationally!

I would like to thank all ACP members for having dedicated time and effort in raising the awareness of prosthodontics once again this year, and look forward to an even more successful NPAW 2015! ■

For a complete list of activities, visit [GoToAPro.org/NPAW](http://GoToAPro.org/NPAW).



## NPAW 2014: Selected Activities

### Pro Bono Care/Oral Health and/or Cancer Screenings

- Louisiana: The Oral Cancer Foundation hosted Louisiana's first Oral Cancer Walk/Run for Awareness at the Pennington Biomedical Research Center in Baton Rouge. Free oral cancer screenings were offered.
- New Jersey: Dr. Cortese donated his fees from teeth whitening to Smiles for Life, a charitable initiative devoted to promoting oral health among underserved children.
- Massachusetts: Boston University had free consultations for new patients and free oral cancer screenings.
- Maryland: Members of the MD Section hosted an oral cancer screening and caries detection for families at the Esperanza Health Center. The section also donated \$500 in dental supplies to the center. Fifty patients were screened.
- Iowa: Residents made dentures for five homeless patients.

### Press Coverage

- Massachusetts: ACP Spokespersons Network member Dr. Spitz was featured in *USA Today* regarding digital dentistry and lasers, and identified as a prosthodontist.
- New York: ACP Spokespersons Network member Dr. Tuminelli was featured in an article for *Inside Dental Technology*.
- New York: Dr. Fagin appeared on *WKBW Morning Buffalo* to discuss NPAW, prosthodontists, and organizations in the Buffalo area that provide pro bono dental care to members of the public in need.
- Maryland: ACP Spokespersons Network member Dr. Obeid and his patient were featured in *CNN Health Minute* regarding digital technology and dentures.
- Pennsylvania: ACP Spokespersons Network member Dr. Bentz discussed NPAW and the work



Maryland: Dr. Obeid held an oral cancer screening at a local senior center. 23 patients were screened. Dr. Obeid was also featured in a health minute report.

that prosthodontists do on *Talk Philly Live* (CBS TV).

- West Virginia: Dr. Felton and Dr. Richards appeared in a local Fox TV News segment about NPAW. Dr. Felton also did a 2nd interview during NPAW for *Fox TV News*.
- Tennessee: ACP Spokespersons Network member Dr. Chesser was featured in *Angie's List Magazine* about tooth whitening.
- California: ACP Spokespersons Network member Dr. Wei contributed to an article about bacteria and toothbrushes for Grandparents.com. The article got picked up and republished by the *Huffington Post*, the *New York Post* and the *Times of India*.
- Florida: Dr. Nawrocki promoted NPAW during a TV segment for *First Coast Living*.

### Open Houses

- Massachusetts: Tufts held an open house for D.M.D. students and the faculty gave presentations.
- Pennsylvania: Dr. Balshi and Pi Dental had an open house for prospective and current patients, referring doctors, staff, vendors, and the community. Goodie bags and treatment gift cards were given away.

## NPAW 2014: Selected Activities

### Professional Presentations

- California: Dr. Baba gave a presentation to 12 of his referrals (oral surgeons, periodontists, orthodontists, and endodontists) showing many clinical cases.
- Connecticut: Residents distributed brochures on prosthodontics and demonstrated prosthetic treatment models. Residents also participated in the UConn Health Center 'Health Expo' reaching out to the public and hospital staff.
- New Jersey: At Rutgers, Dr. DiPede gave presentations to each class, from freshmen to seniors.
- New York: During Postgraduate Week at NYU, Dr. Jahangiri and Dr. Choi invited dental students to Q&A sessions. Residents showed their cases.
- North Carolina: Dr. Scruggs and his staff delivered donuts, marketing items, and fact sheets to 40 referring practices.
- Ohio: The Department of Comprehensive Care at Case Western Reserve University, School of Dental Medicine organized a lecture. Prosthodontists presented some complex cases.
- Wisconsin: Marquette University School of Dentistry, Postgraduate Program on Prosthodontics presented a 4 hour CE course to about 25 attendees.
- Colorado: Drs. Batson and Pickle gave a two-day course on restoring dental implants. Dr. Batson discussed CAD/CAM advancements with the U.S. Army Ft. Carson AEGD residents.
- Idaho: Drs. Ruppel and Gurney sponsored dinner for a meeting of the High Desert Hygiene Study Club.
- Nevada: The NV Section provided a free CE course with the Las Vegas Dental Association.



Ohio: Drs. Peregrina, Lloyd, Knoblach, Saponaro, and Salata presented cases.



Connecticut: UConn residents held a Lab Open House for dental students. Residents showed "tricks of the trade" such as waxing techniques, fabrication of a surgical guide, beautifying casts, and festooning dentures.

### Lunch & Learns

- Connecticut: Post-graduate residents collaborated with the pre-doctoral Prosthodontics Interest Group to sponsor a lunch & learn; Dr. Bidra gave a presentation and a few clinical cases.
- Iowa: Drs. Holloway, Boza, Garaicoa, and Stanford delivered presentations to all dental students, faculty, and staff.
- Oregon: Dr. Spink spoke to third and fourth year students about prosthodontic residencies and being in private practice.

### Community Public Outreach

- Kansas: Dr. Amet and his staff helped out a kindergarten class in Colorado and did a dental evaluation of "Flat Stanley" to raise awareness about the importance of a healthy mouth.
- New York: Dr. Fagin organized a gathering of regional and University at Buffalo Dental School dentists, and Mayor Byron Brown issued a proclamation recognizing NPAW.
- Ohio: OSU Staff, faculty, and residents handed out flyers and brochures to patients about dental implants and denture care.
- Oregon: Dr. Over developed a dental preceptorship for his local high school to be offered to a student who has an interest in dentistry.

# Innovation

Don L. Waters

Since its founding in 1976 by Peter Brasseler, our Company has been known for offering high-quality products and being an innovator in the dental industry. In fact, innovation is so much a part of Brasseler USA's culture that our employee newsletter is named "The Innovator".

Our Company's mission is providing innovative and efficient instrumentation you can trust. We develop solutions through a combination of material science, engineering know-how, manufacturing excellence, and practitioner testing to real world challenges.

Brasseler USA's product development process focuses on identifying needs of dental practitioners, and prosthodontists have been a key customer segment from the start. We constantly speak with doctors and lab technicians about the most current esthetic techniques and new materials and related challenges they face in the operatory. We also work with dental educators and teaching clinicians to identify future procedural trends and expected practitioner needs.

Former Apple CEO Steve Jobs once said, "Innovation is not about saying 'yes' to everything. It's about saying 'no' to all but the most crucial features." When our Innovations Team considers bringing a new product to market, they must answer a few key questions. Does the new product provide a significant advantage over products currently available? Will this new product lead to improved outcomes for patients? Will the new product save the practitioner time or money? Will it provide better, more predictable results? Only those concepts which generate positive answers to these questions move forward to the initial development phase.

We took a customer-centric approach when we developed our latest innovation, the DuraBrazed<sup>®</sup> diamond. Durabrazed is engineered to address two "real-world" issues discovered via discussions with practitioners. First, the need for a crown and bridge preparation with a smoother surface and a more

accurate finish line with enhanced marginal fidelity, both of which are critical to precise scans required by digital dentistry. Second, to create a diamond instrument that maintains greater cutting efficiency

over the life of the instrument... particularly important when a patient presents with the need for multiple preparations. A diamond instrument's cutting effectiveness generally degrades due to dislodging of diamond crystals from the instrument and through the clogging of the diamond matrix by tooth debris. Durabrazed employs a patented SpotBrazing<sup>™</sup> technology that permanently adheres the diamond crystals to the instrument at a controlled height and with controlled spacing. The result is a truly innovative product that delivers what practitioners requested: smoother margins and maximum cutting efficiency over a longer time period.

In 1976, we introduced the E-Cutter<sup>®</sup>, a unique instrument used to trim chrome, acrylic, and stone. It remains a top-selling lab cutter 38 years later. Our market-leading rotary product line has expanded over the years to include many innovative restorative procedural solutions for prosthodontics, including our new Durabrazed diamond. We stand ready to serve the needs of American College of Prosthodontists members, both now and in the future. ■



The DuraBrazed<sup>®</sup> diamond, created using SpotBrazing<sup>™</sup> technology, is a prime example of how Brasseler USA continues to innovate and advance dental instrumentation.

# Collaboration and key considerations

Carl F. Driscoll, D.M.D., F.A.C.P.  
Annual Session Program Chair

Over the next few years, several questions will emerge in your practice. No matter your level of clinical skill and knowledge, you will be faced with a case that requires multidisciplinary treatment for a successful outcome. No matter your diagnostic expertise, you will have a brush with litigation.

Are you ready? That's the goal of the ACP's 44th Annual Session.

Thursday morning is an opportunity to calibrate your clinical knowledge and benchmark your skills with presentations by an oral surgeon, a pharmacologist, and several experienced practitioners from other disciplines.

From the very earliest stages of planning, what discussions need to occur between specialists? When developing a treatment plan, what do you need to know about your patient's medications – including many that may not have been approved when you were in school? When complications arise, when can collaboration with an endodontist or a periodontist best serve the patient?

In the afternoon, we're looking to avoid legal headaches with careful management. You may be asked to redo a full-mouth rehabilitation, preparing not only to provide a successful outcome but also to arbitrate between the patient and the previously-treating doctor. How do you proceed with difficult and litigious patients? Through a case study involving mechanical and laser surgical violations of the biologic width that led to a malpractice lawsuit (and a large plaintiff judgment), and tips on how to handle common areas of attack during cross examination, you'll be better prepared.

As a prosthodontist, your advanced training prepares you to provide exceptional patient outcomes. The ACP Annual Session brings that training up to date – and delivers important learning that wasn't part of your residency.

Visit [acp44.com](http://acp44.com) and register to join us in New Orleans for the premier prosthodontic meeting of the year!






## Present your work at the ACP Annual Session

Residents and dental students are invited to present a **Table Clinic** at the ACP Annual Session. The Table Clinics Competition is scheduled for Thursday, Nov. 6. A table clinic can be a presentation of research results, clinical outcomes, laboratory techniques, or topics of general interest to the ACP's members and guests. Two judged competitions will be conducted at the table clinics session: for prosthodontics residents and for dental students. Winners will receive cash awards and invitations to the Annual Awards Dinner as guests of the ACP. The application deadline is **Aug. 15**.

ACP members are encouraged to submit an abstract for an oral presentation at the **Member Speaker Forum**, which will take place on Friday, Nov. 7 at the Annual Session. Time allotments are limited and papers will be selected based on scientific content, submission date, and available time. The oral presentations are restricted to a 15 min. time allotment: 12 min. for presentation and 3 min. for questions. The application deadline is **Aug. 15**.

Visit [acp44.com](http://acp44.com) for more information and to download applications.



The first place winner of the 2013 Postgraduate Competition, Peterson Huang, D.M.D., pictured with Dr. Caroline H. Nguyen, Table Clinics Chair.

## Complications and Treatment from our Co-Specialists

*Moderators: Stephen M. Parel, D.D.S., F.A.C.P. and Debra H. Cohn, D.D.S.*

### **Occlusion-Driven Maxillofacial Reconstruction: Unthinkable without Digital Planning and CAD/CAM Printing**

Dennis Rohner, D.M.D., M.D.

### **Total Face, Double Jaw, and Tongue Transplantation: An Evolutionary Concept Using CAD/CAM Technology**

Branko Bojovic, M.D.

### **There's No Magic in a Patient's Medications**

Harold L. Crossley, D.D.S., M.S., Ph.D.

### **Endodontics in the Digital Age: Basic Principles and New Horizons**

Ashraf F. Fouad, D.D.S., M.S.

### **Real-Life Prosthodontics: Misadventures (Complications) and Magic of Collaborative Treatment**

Stuart J. Froum, D.D.S.

## Diagnostic Considerations and the Legal Consequences That Follow

*Moderator: Robert M. Taft, D.D.S., M.S., B.A., F.A.C.P.*

### **Legal, Ethical, and Management Considerations for the Prosthodontist: Retreating a Full Mouth Rehabilitation**

John A. Sorensen, D.M.D., Ph.D., F.A.C.P.

### **Dentoalveolar Extrusion – The Most Difficult Patient in Dentistry**

Bill Robbins, D.D.S., M.A.

### **Gummy Smile Treated with Laser Surgery – Clinical and Legal Outcomes**

David W. Eggleston, D.D.S., F.A.C.P.

### **Prosthodontic Treatment Outcomes – A Legal Perspective**

Donna L. Dixon, D.M.D., M.A., J.D.



### In the Latest *Journal of Prosthodontics*

Drs. Mamta Mehra, Farhad Vahidi (pictured), and Robert W. Berg present the results of a survey meant to identify current trends in complete denture impression making and to determine the techniques and materials taught in U.S. postdoctoral prosthodontic programs. While others have previously reported similar results for predoctoral students, this is the first to report the results for postdoctoral programs.

With an impressive 87% response rate, the survey provides a good picture of the techniques, materials, and systems prosthodontics residents are learning. Among the results, the authors found that “the most commonly used material for the preliminary impression was irreversible hydrocolloid and for the final impression was PVS; modeling plastic impression compound was used by most programs to border mold the custom trays in sections; the predominantly used impression philosophy across the postdoctoral prosthodontic programs was selective pressure; a majority of the programs made a special consideration for excessive movable (flabby) tissue—most often by placing a window in the custom tray; and most programs advised their patients to not wear their existing dentures for at least 24 hours before the final impressions were made.”

Thanks to all who responded to this survey, which provides valuable insight into the education of new prosthodontists.

Citation: Mehra M, Vahidi F, Berg RW: A complete denture impression technique survey of postdoctoral prosthodontic programs in the United States. *J Prosthodont* doi: 10.1111/jopr.12099



### Predocutorial & Postgraduate Educators Meet in Chicago

More than 100 predoctoral and postgraduate educators met in Chicago, April 4-5 to discuss current issues in prosthodontic education.

The predoctoral educators focused on curriculum guidelines for several key topics, from implants and digital dentistry to treatment planning, while the postgraduate session delved into new competency standards, exam updates, and sharing of ideas between programs.

These meetings will reconvene in New Orleans, Nov. 5 at the ACP Annual Session.



### ACP member appointed Dean at UIC College of Dentistry

ACP member Dr. Clark M. Stanford has been appointed as Dean of the University of Illinois at Chicago, College of Dentistry, effective October 1, 2014, pending Board of Trustees approval.

Dr. Stanford is currently the Associate Dean for Research and Centennial Fund Professor for Clinical Research in the Dows Institute for Dental Research and the Department of Prosthodontics at the University of Iowa College of Dentistry.

“Clark Stanford is a star hire,” said Lon Kaufman, UIC vice chancellor for academic affairs and provost. “His illustrious career as a clinician-scientist and faculty administrator has prepared him perfectly to lead one of the best colleges of dentistry in the country.”

## Upcoming Events

Sept. 12-13, 2014

### Prosthodontic Review Course

American College of Prosthodontists  
Chicago

[GoToAPro.org](http://GoToAPro.org)

Nov. 5-8, 2014

### 44th Annual Session

American College of Prosthodontists  
Hyatt Regency,  
New Orleans

[acp44.com](http://acp44.com)

April 12-18, 2015

### National Prosthodontics Awareness Week

[GoToAPro.org/NPAW](http://GoToAPro.org/NPAW)

## Dive the archives at [acpmessenger.org](http://acpmessenger.org)

Every issue of the ACP *Messenger*, from tablet-optimized digital editions of the current magazine to the very first newsletter (from January 1973), is laid out for easy browsing at the new [acpmessenger.org](http://acpmessenger.org). Scroll through the years and enjoy!

## ACP MESSENGER

Winter 2014



Leading, planning, healing  
Cutting edge dental implant technology  
Prosthodontics: A dynamic specialty



## Call for Applications: Granger-Pruden Memorial Award for Excellence in Dental Research

The Northeastern Gnathological Society honors the memory of Ernest R. Granger and William H. Pruden II each year by offering the Granger-Pruden Award. This award of \$2,500 is given to support research in prosthodontics and related materials science.

The recipient of this award will be invited as a guest to present his or her research at the NGS Scientific Seminar in New York City where he or she will be recognized. The 2013 winner was Dr. Abhinav Wadkar from Rutgers University.

Application forms are available online at: [http://ngsorg.org/Granger\\_Pruden\\_Award.html](http://ngsorg.org/Granger_Pruden_Award.html). Applications may be submitted beginning Sept. 1 via email to [dr.reena.varghese@gmail.com](mailto:dr.reena.varghese@gmail.com). The deadline for submission is Oct. 15, 2014.

## Welcome New Members

March 2014 – June 2014

### Reinstated Fellows

Dr. P. Andrew Benson  
Dr. Melani Kapetanakos

### New Members

Dr. Christopher D. Fellows  
Dr. Rick A. Jude  
Dr. Ernesto R. Schwedhelm

### Reinstated Members

Dr. Roman M. Cibirka  
Dr. Anthony M. Deliberato  
Dr. Walter J. Leckowicz, Jr.  
Dr. Michiko Maeda

### Honorary Members

Dr. Urs C. Belser  
Dr. Robert Gottlander  
Dr. Bach T. Le

### New Global Alliance Member

Dr. Hasan Necdet Alkumru

### Reinstated Global Alliance Member

Dr. L. Marcela Ibarra

### New Dental Technician Alliance Member

Mr. Gregory A. Wallace

### New Student Members

Dr. Brian C. Aguirre  
Dr. Omar M. Alaryani

Dr. Prokopios Antonellis

Dr. Randold A. Binns

Dr. Seth H. Bozarth

Dr. Christopher W. Coffey

Dr. Jonathan Hunter Dawson

Dr. Robert K. Gazdeck

Dr. Sanjay Karunakaran

Dr. Hyemi Kim

Dr. Alex J. Matosian

Dr. Tien M. Ha-Ngoc

Dr. Oswaldo A. Nieves Vaca

Dr. Nicholas G. Norvell

Dr. Miguel Angel Ortiz

Dr. Stuart R. Schelkopf

Dr. Christina M. Schiltz

Dr. Steven A. Williams

Dr. Stephanie K. Zeller

### New Predoctoral Student Alliance Members

Mr. Zachary Daniel Danowitz

Ms. Ashley D. Morgenstern

Ms. Annie Liou

Mr. Austin L. Lyman

Mr. Justin K. Terrill

Mr. Claus J. Ullstad

### Advanced Program and Graduate Studies Alliance

Dr. Qiuyi Liang

## Job Opportunities

**California (Palm Desert)** – Great extra income opportunity! Palm Desert, CA multi-specialty practice looking for Board Certified Prosthodontist. Earn extra \$100K/yr. working 2 days/mo. If interested send CV to: [golfinthedesert@gmail.com](mailto:golfinthedesert@gmail.com) or contact (760) 272-6292. Website: [palmdesertimplantdentist.com](http://palmdesertimplantdentist.com)



**Florida (Naples)** – Career opportunity available in beautiful Naples, Florida. Associate position available for the right candidate at Bayview Dental Arts. Located directly on the water on Naples Bay. BayView Dental Arts is a truly unique specialty practice with state of the art equipment including advanced digital CAD/CAM lab and Zeiss microscopes located in the operatories and laboratories. Check out our beautiful office at [bayviewdentalarts.com](http://bayviewdentalarts.com) to view this one of a kind practice. This opportunity is available only to a prosthodontist of the highest caliber and clinical ability.

Interested individuals should submit a letter of interest and current curriculum vitae via e-mail to [office@bayviewdentalarts.com](mailto:office@bayviewdentalarts.com)

**Florida (University of Florida)** – The University of Florida ([www.dental.ufl.edu](http://www.dental.ufl.edu)) is recruiting a Clinical Assistant/Associate/ Full Professor in the Department of Restorative Dental Sciences, Division of Prosthodontics. Responsibilities will center on pre-doctoral and graduate level didactic, pre-clinical and clinical instruction, participation in intramural faculty practice, and research. Apply online at <https://jobs.ufl.edu>, search for requisition 0905446.

**Georgia (Lawrenceville)** – Prosthodontist Opportunity: Modern, prosthodontic practice is looking for a right associate with partnership opportunity. Knowledge of

Spanish is a plus. Fully equipped lab, digital radiography, cone beam CT scan. Georgia Prosthodontics Smile Specialists. Lawrenceville, GA. Email: [mysmilesthis@gmail.com](mailto:mysmilesthis@gmail.com)

**New York and Vermont (Delmar, NY or Brattleboro, VT)** – 1st Advantage Dental is an established multi-specialty group practice with locations in New York, Massachusetts, and Vermont. Whether it's the Capital District of New York or the beautiful Pioneer Valley of Vermont, we are committed to providing the best possible oral health care to our patients. We are interested in speaking with candidates for full time in Delmar, NY and part time in Brattleboro, VT. Send CV & Cover Letter to [kateanderson@amdpi.com](mailto:kateanderson@amdpi.com)

**Oklahoma (Tulsa)** – Outstanding opportunity for progressive Prosthodontist to join existing implant based practice in Oklahoma. This opportunity is a private practice based and not affiliated with a corporate DSO. This is a practice develop opportunity with unlimited potential. Oklahoma is an excellent place to live and raise a family. Low cost of living, stable economy, excellent public and private schools, and a plethora of beautiful lakes are just a few of the advantages of living in Oklahoma. For additional information please send resume and contact information to [tttranch22@gmail.com](mailto:tttranch22@gmail.com)



**Oklahoma (University of Oklahoma)** – Prosthodontics. Three full-time Assistant/ Associate Professor positions available immediately or until positions are filled. Responsibilities in undergraduate preclinical and clinical courses in Fixed, Removable and Implant dentistry. Must have DDS/DMD from CODA accredited dental school or foreign equivalent and

completion of Part I and Part II of National Dental Board Examinations. Master's degree or Certificate in Prosthodontics from CODA accredited dental school preferred. Experience in dental education preferable and eligibility for Oklahoma dental licensure required. Intramural practice is available. Salary and rank commensurate with qualifications and experience. Applicants will be reviewed as received. Send curriculum vitae and a list of three references to: Dr. Paul Mullasseril; Chair, Restorative Dentistry; University of Oklahoma Health Sciences Center; College of Dentistry; PO Box 26901, Oklahoma City, OK 73126. The University of Oklahoma is an Equal Opportunity Employer. Individuals with disabilities and protected veterans are encouraged to apply.



**South Carolina (Medical University of South Carolina)** – The James B. Edwards College of Dental Medicine (JBECDM), Medical University of South Carolina, Charleston, SC seeks applications for a full-time tenure track position to serve as the Chair of the Department of OR/P available July 1, 2014. The Department is a significant component of the JBECDM and is organized into the Divisions of Endodontics (undergraduate and graduate), Implant Prosthodontics, Restorative Dentistry (Fixed and Operative Dentistry) and Removable Prosthodontics. The AEGD Program is also administered by the Department of OR/P. Requirements for the position include: a DDS/DMD from an accredited US/Canadian Dental School; board eligibility or current certification by the American Board of Prosthodontics; demonstrated academic dentistry leadership ability; a broad range of competency in patient care; predoctoral and postdoctoral teaching; and documentable research



experience. Responsibilities include broad range leadership, coordination and participation in the didactic, preclinical, and clinical instruction at the predoctoral and postdoctoral levels, and participation in the research and continuing education activities of the department. Salary and rank commensurate with qualifications and experience. MUSC is an EEO/AA employer—minorities and women encouraged to apply. Please send a letter of interest, current CV and three letters of recommendation addressed to Dr. Tariq Javed c/o Mrs. Shelley Garvin (electronic submission preferred) to garvins@musc.edu or to JBECMD, MUSC, 173 Ashley Avenue, MSC 507, BSB 447, Charleston, SC 29425

**Texas (Austin)** – Opportunity for a Prosthodontist to join our prosthodontic/implant/general practice. High income potential. Please email your resume to austinprosthodontics@yahoo.com



**West Virginia (West Virginia University)**– West Virginia University School of Dentistry is seeking applications for two full time clinical or tenure track faculty positions at the Assistant/Associate Professor level in the Department of Restorative Dentistry. Applicants should be experienced Prosthodontists and/or Restorative Dentists. Responsibilities will include pre- and post-doctoral didactic and clinical teaching in prosthodontics, restorative dentistry, scholarly activity, and faculty practice. Candidates must be eligible for a West Virginia dental license; information regarding licensure in WV can be obtained at [www.wvdentalboard.org](http://www.wvdentalboard.org). The Department of Restorative Dentistry currently includes the disciplines of operative dentistry, prosthodontics (fixed, removable, and implant prosthodontics) and

dental materials. A successful candidate will have a history of documented competence in teaching, administration and research and will demonstrate excellent interpersonal and communication skills. Individuals with experience in curriculum development and revision are encouraged to apply.

West Virginia University School of Dentistry is located in the historic community of Morgantown, West Virginia. A thriving economy, dynamic university community, nationally ranked school system, four season climate, and breathtaking scenery make Morgantown a very attractive place to relocate professionally and personally. Over the past four years, Morgantown has ranked nationally among the very best small cities in the US for quality of life. Located only 75 miles south of Pittsburgh, Morgantown is easily accessible to major metropolitan areas in the East and Midwest.

Review of applications will begin immediately and will continue until the position is filled by a qualified candidate. Salary will be commensurate with qualifications and experience. Interested individuals should submit a letter of interest, current curriculum vitae and names, addresses and phone numbers of three references to Dr. Matthew Bryington, Assistant Director of Graduate Prosthodontics, Department of Restorative Dentistry, West Virginia University School of Dentistry, P.O. Box 9495, Morgantown, WV 26506-9495. West Virginia University is an Affirmative Action/Equal Opportunity Employer. WVU Health Sciences Center is a smoke free campus. West Virginia University is the recipient of an NSF ADVANCE award for gender equity. For more information on the School of Dentistry and Health Sciences Center see [www.hsc.wvu.edu/sod](http://www.hsc.wvu.edu/sod) or [www.hsc.wvu.edu](http://www.hsc.wvu.edu).

**Wisconsin (Green Bay)** – State-of-the-art prosthodontic practice seeks a Dental Laboratory Technician. Position requires

laboratory experience, professional attitude, high energy level, and attention to detail. Please submit resume to: [patricia@drnickgreenbay.com](mailto:patricia@drnickgreenbay.com)  
Dr. Nick AbuJamra DDS MS

**Wisconsin (Green Bay)** – VA Great Lakes Health Care System's new clinic in Green Bay, Wisconsin, will serve up to 20,000 veterans. We seek a full-time Dual Certified Prosthodontist / Oral Maxillofacial Radiologist proficient in:

- All aspects of fixed / removable / implant prosthetics
- All aspects of Oral Maxillofacial Radiology
- Treatment planning for complex cases
- Working with general dentists to achieve optimal results
- General dentistry procedures such as amalgam and composite restorations, simple extractions, and minor oral surgery
- Education of dental residents

MUST BE BOTH A B/C Prosthodontist and a B/C Oral Maxillofacial Radiologist.

Requires:

- Degree of doctor of dental surgery or dental medicine resulting from a course of education in dentistry obtained from one of the schools approved by the Secretary of Veterans Affairs for the year in which the course of study was completed. Approved schools are:
- United States and Canadian schools of dentistry listed by the Council on Dental Education, American Dental Association, in the list published for the year in which the course of study was completed.
- Schools (including foreign schools) accepted by the licensing body of a State, Territory, or Commonwealth (i.e., Puerto Rico), or the District of Columbia as qualifying for full and unrestricted licensure provided the licensure requirements include a written examination measuring science

achievement and a performance examination measuring clinical competence.

- Current, full, and unrestricted license to practice dentistry in a State, Territory, or Commonwealth of the U.S.A. (i.e. Puerto Rico), or in the District of Columbia. Must maintain current registration in the State of licensure if this is a requirement for continuing active, current licensure. The facility Director may waive this licensure requirement if the dentist is to serve in a country other than the U.S.A. and the dentist has licensure in that country.
- Credentials necessary to obtain affiliate medical school appointment.
- Subject to random testing
- Complete a background security investigation
- Occasional travel
- Pre-employment medical examination

Green Bay, Wisconsin, population: 105,809 (2011), is home to Lambeau Field, Green Bay Botanical Gardens, Bay Beach Amusement Park, New Zoo, Oneida Bingo/Casino, and an array of restaurants, shopping, golf courses, parks, and more. Exceptional colleges, high schools, and middle/grade schools in a family-friendly community make Green Bay a great place to live.

Competitive salary and excellent benefits package. Questions may be directed to Jake Goldenstein: 414-384-2000, x42936

Forward a cover letter and CV:

Clement J. Zablocki VA Medical Center  
Jacob Goldenstein, HRM Building 05  
5000 W. National Avenue  
Milwaukee, WI 53295  
E-mail: Jacob.goldenstein@va.gov.  
Fax: 414-382-5296.

Equal Opportunity Employer

## Practices for Sale

**California (Palm Desert)** – State of the art specialty practice established in 1992. Digital pano, Dentrix, 5 ops, ADEC equipment, 2,600 sq ft. Prosthodontist that also places implants best candidate. Adding referrals doubles profits. Need to move out of state. Asking \$450k. Serious inquiries only. Kept confidential. Email contact info to: [golfinthedesert@gmail.com](mailto:golfinthedesert@gmail.com)

**California (San Francisco)** – High Quality and state of the art prosthodontic practice for sale in downtown San Francisco. For more information, please send a cover letter and current CV to [molinelli@aol.com](mailto:molinelli@aol.com) or call Stephen Molinelli of Northern California Practice Sales at 650-347-5346.

**Hawaii (Maui)** – Comprehensive Maui restorative practice. All phases of prosthodontics, perio, implant placement. In practice over 30 years. Dr. desires to complete existing cases in the transfer of the practice. Excellent opportunity to grow the practice on the best island in the world. Email: [mauiddsmsd@yahoo.com](mailto:mauiddsmsd@yahoo.com) or (808) 205-2432.

**Kansas (Overland Park)** – Practice For Sale: Great Collections – Over 750K/Year Only 3 Days/Week. Excellent New Patient Flow From Developed Marketing – Over 25/Month. Latest Technology – CAD/CAM, Lasers, Digital X-Rays, 3D iCat, Implant Systems. Large Cases and Advanced Treatment Protocols - Great Staff Willing to Stay. Please call or email Kyle Francis with Professional Transition Strategies: 719-459-1021 [kfrancis@professionaltransition.com](mailto:kfrancis@professionaltransition.com).

**Washington (Seattle)** – Prosthodontic practice for sale in the greater Seattle area. A rare and unique opportunity! An outstanding practice with high production and very high profitability and cash flow. Building is in a great location with plenty of parking and visibility. Building could eventually be for sale to prospective buyer. Experienced staff will stay on with the practice. Owner also would stay on 1-2 days per week for up to a year to ensure a smooth and complete transition. On-site lab. Contact Buck Reasor, DMD. Cell: 503-680-4366. Fax: 888-317-7231. Email: [info@reasorprofessional dental.com](mailto:info@reasorprofessional dental.com) Website: [www.reasorprofessional dental.com](http://www.reasorprofessional dental.com)

**Washington (Spokane)** – Spokane, Washington practice for sale. Unique opportunity in the beautiful Pacific Northwest. Prosthodontic practice just miles from endless year round outdoor recreation. Heavy emphasis on crown and bridge and implant reconstruction. Very strong net and a solid corner in prosthetic dentistry as the only prosthetic practice in North Spokane. There are two full time and one part time prosthodontic practices in the entire city and county. This practice features 6 ops and an active hygiene department and is located in a 2-story professional building with a periodontist, an orthodontist and 4 general practices. Current lease is up on 8/31/2017 with a 5 year option available. Doctor will stay for transition period if desired. Call: O 509-327-4469, C 509-688-9288 or email: [retoother@hotmail.com](mailto:retoother@hotmail.com)

# Restoring quality of life

Patients rely on you in order to eat, speak, and smile with confidence. It can be said, you are actually restoring quality of life.

To succeed, you need technology that is well founded and documented in science. That is why we only deliver premium solutions for all phases of implant therapy, which have been extensively tested and clinically proven to provide lifelong function and esthetics.

Moreover, with an open-minded approach, we partner with our customers and offer services that go beyond products, such as educational opportunities and practice development programs.

***Reliable solutions and partnership for restoring quality of life ... because it matters.***

These products may not be regulatory cleared/released/licensed in all markets. 3267000.04.US.1402 © 2014 DENTSPLY. All rights reserved

[www.dentsplyimplants.com](http://www.dentsplyimplants.com)

**ANKYLOS®**

**ASTRA TECH  
IMPLANT SYSTEM**

**XiVE®**

**ATLANTIS™**

**SIMPLANT®**

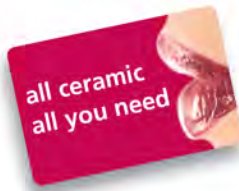**SYMBIOS®**

**DENTSPLY  
IMPLANTS**

IPS e.max<sup>®</sup>

“BECAUSE IT  
**WORKS**”

THE WORLD'S MOST TRUSTED\* ALL-CERAMIC SYSTEM



More and more dentists and technicians rely on IPS e.max, the clinically proven all-ceramic system that offers high esthetics and outstanding strength. Over 6000 North American laboratories and 75 million restorations placed\* prove IPS e.max works. For crowns, inlays, onlays, thin veneers, abutments and bridges – make the choice more dental professionals make... **MAKE IT e.max!**

  [ivoclarvivadent.com](http://ivoclarvivadent.com)

\*Ivoclar Vivadent global usage data  
For more information, call us at 1-800-533-6825 in the U.S., 1-800-263-8182 in Canada.  
© 2014 Ivoclar Vivadent, Inc. Ivoclar Vivadent, IPS e.max is a registered trademark of Ivoclar Vivadent, Inc.

  
ivoclar  
vivadent<sup>®</sup>  
passion vision innovation